



Access this article online

Quick Response Code:



Website:

[www.turkjemergmed.com](http://www.turkjemergmed.com)

DOI:

10.4103/2452-2473.366488

# Transient ischemic liver injury and respiratory failure in a COVID-19-positive patient after multiple bee stings

Onder Yesiloglu, Ahmet Sonmez<sup>1</sup>, Begum Seyda Avci<sup>2</sup>, Hilmi Erdem Sumbul<sup>2</sup>, Akkan Avci<sup>1\*</sup>

Emergency Medicine Clinic, Gaziantep 25 Aralik State Hospital, Departments of <sup>1</sup>Emergency Medicine and <sup>2</sup>Internal Medicine, Health Science University, Adana City Research and Training Hospital, Adana, Turkey  
\*Corresponding author

## Abstract:

We present a patient with multiple bee stings who developed lung and liver injuries and subsequently tested positive for coronavirus disease 2019 (COVID-19). A 65-year-old male patient presented to the emergency department after being stung by more than 100 honeybees. His physical examination revealed pustular lesions distributed across his chest, arms, back, legs, and head, marking the sting zones. While the patient had no history of liver disease, initial laboratory test results showed elevated liver enzyme levels. A chest computer tomography scan was ordered, revealing bilateral ground-glass opacities suggesting COVID-19. His condition worsened over the course of the following day, and when he was admitted to the intensive care unit (ICU), his SpO<sub>2</sub> decreased to 83% despite oxygen support with a mask. The second polymerase chain reaction test taken in the ICU was positive for COVID-19 infection. After stung with multiple bees, the patient developed acute liver injury and suffered from concomitant COVID-19-related respiratory insufficiency, and he was treated accordingly. Starting on the 5<sup>th</sup> day, the patient's liver markers began to improve, and on the 13<sup>th</sup> day, he was discharged with normal vital signs and liver enzyme values. There seem to be varying outcomes across different studies with regard to the relationship between bee stings and COVID-19. Further research is needed to explore the possibility of this complementary treatment with bee venom in the prevention of severe acute respiratory syndrome coronavirus-2 infection.

## Keywords:

Acute hepatitis, bee sting, bee venom, COVID-19, liver injury, severe acute respiratory syndrome coronavirus-2

Submitted: 05-03-2022

Revised: 18-05-2022

Accepted: 18-05-2022

Published: 02-01-2023

## ORCID:

OY: 0000-0003-0149-8456

AS: 0000-0001-9175-0509

BSA: 0000-0001-6149-9341

HES: 0000-0002-7192-0280

AA: 0000-0002-4627-0909

## Address for correspondence:

Dr. Akkan Avci,

Department of Emergency

Medicine, Adana City

Research and Training

Hospital, Health Science

University, Adana, Turkey.

E-mail: [drakkanavci@](mailto:drakkanavci@gmail.com)

[gmail.com](mailto:drakkanavci@gmail.com)

## Introduction

Since the emergence of the novel coronavirus in Wuhan, Hubei Province, China, in December 2019, researchers have focused their efforts not only on novel vaccines, promising treatment methods, and prophylactic measures but also on complementary and supportive therapeutic possibilities. A number of recent studies

have suggested bee venom as a promising candidate for further investigation regarding the prevention and treatment of COVID-19.<sup>[1,2]</sup> Bee venom is known to contain a number of enzymes and peptides that exhibit multiple anti-inflammatory and antiviral activities.<sup>[2]</sup> However, whether these properties are useful in the treatment and prevention of COVID-19 is still under debate.

In this case, we present a patient with multiple bee stings who developed lung

This is an open access journal, and articles are distributed under the terms of the Creative Commons Attribution-NonCommercial-ShareAlike 4.0 License, which allows others to remix, tweak, and build upon the work non-commercially, as long as appropriate credit is given and the new creations are licensed under the identical terms.

For reprints contact: [WKHLRPMedknow\\_reprints@wolterskluwer.com](mailto:WKHLRPMedknow_reprints@wolterskluwer.com)

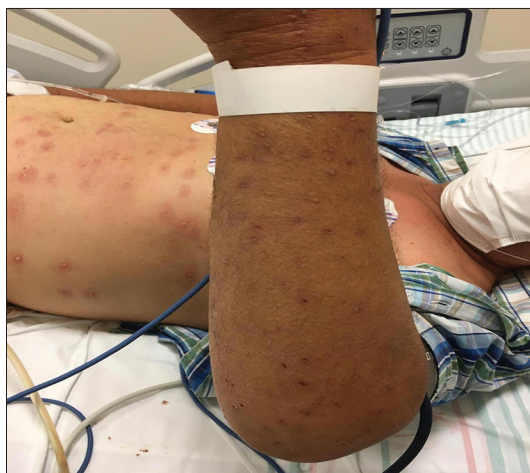**How to cite this article:** Yesiloglu O, Sonmez A, Avci BS, Sumbul HE, Avci A. Transient ischemic liver injury and respiratory failure in a COVID-19-positive patient after multiple bee stings. Turk J Emerg Med 2023;23:57-60.

and liver injuries and subsequently tested positive for COVID-19 disease.

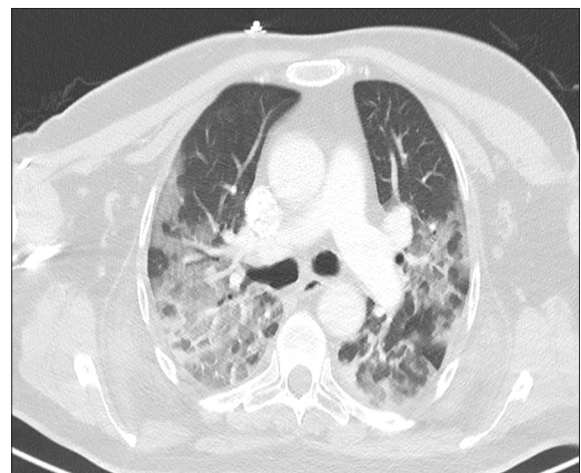
### Case Report

A 65-year-old male patient was referred to the emergency department from a county clinic with initial diagnosis of anaphylaxis due to hypotension with a blood pressure of 80/50 mmHg and flushing developed after being swarmed and stung by more than 100 honeybees in the apiary he worked as a beekeeper. The patient had been administered with 0.5 mg of adrenaline intramuscular injection and 80 mg of corticosteroid (methylprednisolone) intravenous (IV) infusion at the county clinic before his admission to our emergency room. His vital signs at the time of admission were as follows: blood pressure: 150/80 mmHg, pulse rate: 93 bpm, and SpO<sub>2</sub>: 90%. His electrocardiogram was normocardic with sinus rhythm, and his Glasgow Coma Score was 15. His physical examination revealed pustular lesions distributed across his chest, arms, back, legs, and head, marking the sting zones [Figure 1]. There were no other remarkable physical findings on arrival, with normal chest auscultation and no abdominal tenderness or pain. The patient had a previously known history of hypertension, but there had been no drug use in the past 24 h. The patient was admitted to the critical care unit of the emergency department, and oxygen therapy of 4 l/min was initiated. The laboratory results of the patient are shown in Table 1. Laboratory test results showed elevated liver enzyme levels (aspartate aminotransferase [AST]: 1,146 U/L, alanine aminotransferase [ALT]: 878 U/L), elevated lactate levels (49 mg/dl) (N: 9–29 mg/dL), a high level of creatine kinase (2856 U/L) (N: 6–171 ng/L), high INR value (1.57), and a high-sensitive troponin I level of 48 ng/L (N: 0–16 ng/L), with creatinine (0.98 mg/dl) and albumin levels (33.6 g/L) within normal ranges.

Over the course of the day of admission, the patient developed shortness of breath, and his liver enzyme values increased rapidly (AST: 2,054 U/L and ALT: 897 U/L) while troponin I and lactate levels improved, suggesting the injury was limited to the liver. The patient had no history of liver disease and his liver enzymes were within normal range beforehand. Serological results for hepatitis infection were negative, and he did not state previous use of alcohol or of any kind of substance such as wild herbs, mushrooms, or similar. A chest computed tomography (CT) scan was ordered, and it revealed bilateral ground-glass opacities, suggesting either pulmonary edema or COVID-19 [Figure 2]. There were no COVID vaccines in our country at the time being, and the patient had never been abroad. The patient was consulted with internal medicine and cardiology specialists. Although the initial test for COVID-19 was negative and there was no growth severe acute respiratory syndrome coronavirus-2 (SARS-CoV-2) in the culture of pustules' contents, COVID-19 treatment was initiated according to recommendations of the Centers for Disease Control and Prevention along with 500 mg of levofloxacin PO with regard to the chest CT findings. However, his condition worsened over the course of the next day, and when he was admitted to the intensive care unit (ICU), his SpO<sub>2</sub> was 83% despite oxygen support with a mask. Another blood sample was obtained, which revealed elevated D-dimer (1590 µg/L) and ferritin (1060.9 µg/L) values, further increasing the suspicion of COVID-19. Exactly 40 mg of methylprednisolone IV was added to the treatment, and high-flow nasal cannula oxygen therapy was initiated. The second polymerase chain reaction test taken in the ICU was positive for COVID-19 infection. Plasma therapy was administered, and the patient was placed in a prone position at regular intervals. Starting on the 5<sup>th</sup> day, the patient's liver markers began to improve. On the 13<sup>th</sup> day, he was discharged from the



**Figure 1:** His physical examination revealed pustular lesions distributed across his chest and arms, marking the sting zones



**Figure 2:** A chest CT revealed bilateral ground-glass opacities for COVID-19. CT: Computed tomography

**Table 1: Laboratory results of the patient**

	1 <sup>st</sup> day	2 <sup>nd</sup> day	3 <sup>rd</sup> day	4 <sup>th</sup> day	5 <sup>th</sup> day	6 <sup>th</sup> day	7 <sup>th</sup> day	8 <sup>th</sup> day	9 <sup>th</sup> day	10 <sup>th</sup> day	11 <sup>th</sup> day	12 <sup>th</sup> day	13 <sup>th</sup> day
Glucose (mg/dL)		288	311	308	286	279	196	237	120	249	242		207
Urea (mg/dL)	34	36	64	68	66	52	45	51	45	54	47	47	41
Creatinin (mg/dL)	0.56	0.58	0.98	1.1	1.02	0.85	0.68	0.67	0.6	0.64	0.59	0.62	0.65
Sodium (mmol/L)	135	135	137	138	133	136	140	138	138	137	134	135	133
Potassium (mmol/L)	4.04	4.28	4.14	3.94	4	4.22	4.01	4.06	4.84	4.7	5.43	4.38	
ALT (U/L)	22	22	897	986	878	620	272	135	93	65	50	39	34
AST (U/L)	11	13	2054	2141	1146	543	93	28	26	15	21	13	37
Procalcitonin	0.04	0.03					2.37	1.05	0.53	0.3	0.14	0.15	0.17
C-reactive protein (mg/L)	4.49	2.9	35.1	41.9	13.4	8.8	7.06	26.1	74.5	29.3	15.1	40.1	50.4
White blood cell (10 <sup>3</sup> /μl)	12.0	8.5	15.9	16.8	21.3	19.2	19.2	17.8	13.3	10.3	14.3	22.8	19.5
Hemoglobin (g/dL)	10.02	10.1	14.4	14.2	14.4	13.6	13	12.3	10.8	11.1	11.3	11.5	10.8
Hematocrit (%)	29.5	29.1	44.1	43.3	42.9	41.3	38.3	37.4	33.3	32.5	32.7	33.5	31.6
Platelets (10 <sup>3</sup> /μl)	209	222	195	180	203	174	138	123	142	129	144	151	159

ALT: Alanine aminotransferase, AST: Aspartate aminotransferase

internal medicine ward with normal vital signs and liver enzyme values. Written informed consent was obtained.

## Discussion

After recovering from the initial anaphylaxis caused by the swarm of bees, the patient in our case was initially asymptomatic for COVID-19. However, this period of wellness lasted briefly, and the patient developed both shortness of breath and ischemic hepatitis over 24 h, which resulted in the hospitalization of the patient in the ICU. Although he recovered after 14 days, diffuse widespread infiltrations were observed on the chest CT scan on the 2<sup>nd</sup> day, and his condition was unstable, with low SpO<sub>2</sub> rates for the 1<sup>st</sup> week.

There is an ongoing debate as to whether bee venom is protective against complications or can reduce the severity of COVID-19 disease. Bee venom contains a variety of active components, including, but not limited to, enzymes such as phospholipase A2 and peptides such as melittin, apamin, amino acids, phospholipids, and a number of volatile compounds.<sup>[3]</sup> Many of these components have been shown to have anti-inflammatory, antinociceptive, and antioxidant properties,<sup>[4]</sup> while phospholipase A2 has been suggested to have potential antiviral activity.<sup>[5]</sup> Bee venom has also been shown to stimulate the differentiation of FOXP3-expressing cells in CD4 T-cells and mature CD4 thymocytes, both of which play an important role in the immune response against SARS-CoV infection.<sup>[6]</sup> A survey conducted in Hubei Province of 5115 beekeepers showed that none of these beekeepers developed symptoms associated with COVID-19, emphasizing the possible preventive features of bee venom against the disease.<sup>[7]</sup> Conversely, a survey study by Männle *et al.* in Germany showed that out of 234 beekeepers who had contact with SARS-CoV-2-infected people, two beekeepers had died due to complications of COVID-19, and 45 were affected with COVID-19 symptoms, with no significant

difference between the groups in terms of the total number of bee stings received. They also found that the reaction to bee stings and the level of local swelling were correlated with the perceived severity of two symptoms of a SARS-CoV-2 infection.<sup>[8]</sup> The respiratory distress syndrome that developed within 1 day after stung by more than a 100 bees and the subsequent positive swab test suggest that the protective effects of bee venom for COVID-19 disease were not observed in our case, supporting the notion that beekeepers are not immune to the complications of a SARS-CoV-2 infection.

Another complication worth mentioning in our case is acutely developed liver injury, with AST and ALT values as high as 2054 U/L and 897 U/L, respectively. Although the elevated liver enzyme values following more than 100 bee stings may be caused by decreased liver perfusion or hypoxemia due to subsequent anaphylaxis or secondary to respiratory failure,<sup>[9]</sup> increasing evidence demonstrates frequent incidents of liver injury in patients with COVID-19.<sup>[10]</sup> Li and Fan found that liver injury in COVID-19 patients often manifests as a transient elevation of serum aminotransferases,<sup>[10]</sup> which was also the progression of our patient, whose liver enzyme levels returned to normal values after 6 days. Regardless of the cause, our case suggests that the debated beneficial effects of bee venom may not protect individuals from ischemic liver injury.

## Conclusion

The use of bee venom as a complementary treatment for COVID-19 is still not proven in an exact, clear manner, and there seem to be varying outcomes across different studies with regard to this relationship. We believe that additional case reports involving patients stung by bees and positive for COVID-19 and more elaborate multicenter studies are needed to further explore the effectiveness of this treatment possibility.

#### Acknowledgment

There is no person, institution, or company to acknowledge.

#### Author contributions

All authors read the manuscript and agreed to the content and data. All authors played a significant role in the article. All authors accept the publication of the article.

#### Conflicts of interest

None declared.

#### Written patient consent

Informed consent was explained to patient in detail, and patient was included in the study after obtaining written consent.

#### Funding

None.

## References

1. Lima WG, Brito JC, da Cruz Nizer WS. Bee products as a source of promising therapeutic and chemoprophylaxis strategies against COVID-19 (SARS-CoV-2). *Phytother Res* 2021;35:743-50.
2. Kasozi KI, Niedbala G, Alqarni M. Bee venom – A potential complementary medicine candidate for SARS-CoV-2 infections. *Front Public Health* 2020;8:594458.
3. Wehbe R, Frangieh J, Rima M, El Obeid D, Sabatier JM, Fajloun Z. Bee venom: Overview of main compounds and bioactivities for therapeutic interests. *Molecules* 2019;24:2997.
4. Zhang S, Liu Y, Ye Y. Bee venom therapy: Potential mechanisms and therapeutic applications. *Toxicon* 2018;148:64-73.
5. Fenard D, Lambeau G, Valentin E, Lefebvre JC, Lazdunski M, Doglio A. Secreted phospholipases A(2), a new class of HIV inhibitors that block virus entry into host cells. *J Clin Invest* 1999;104:611-8.
6. Caramalho I, Melo A, Pedro E, Barbosa MM, Victorino RM, Pereira Santos MC, *et al.* Bee venom enhances the differentiation of human regulatory T cells. *Allergy* 2015;70:1340-5.
7. Yang W, Hu FL, Xu XF. Bee venom and SARS-CoV-2. *Toxicon* 2020;181:69-70.
8. Männle H, Hübner J, Münstedt K. Beekeepers who tolerate bee stings are not protected against SARS-CoV-2 infections. *Toxicon* 2020;187:279-84.
9. Waseem N, Chen PH. Hypoxic hepatitis: A review and clinical update. *J Clin Transl Hepatol* 2016;4:263-8.
10. Li J, Fan JG. Characteristics and mechanism of liver injury in 2019 coronavirus disease. *J Clin Transl Hepatol* 2020;8:13-7.