



Access this article online

Quick Response Code:



Website:

www.turkjemergmed.com

DOI:

10.4103/2452-2473.342811

Invited Review Article

Auricular avulsion injuries: Literature review and management algorithm

Mohamed A. Al-Ali^{1,2}, Fikri M. Abu-Zidan^{1*}

¹Department of Surgery, College of Medicine and Health Sciences, United Arab Emirates University,

²Department of Otolaryngology, Al Ain Hospital, Al Ain, Abu Dhabi, United Arab Emirates

*Corresponding author

Abstract:

Traumatic ear avulsion (TEA) may have tremendous psychological consequences if not managed properly. There are no clear guidelines on the surgical management of these injuries, especially in developing countries where microsurgical facilities are lacking. We aimed to review the literature on surgical management of TEA with the main focus on direct re-attachment (DR) so as to develop a surgical management algorithm that can be applied in the absence of microsurgical facilities. We performed an extensive review of the relevant English literature on papers indexed in PubMed describing TEA repaired with DR without restriction to a specific publication time window. A total of 28 cases in 18 publications were reviewed and analyzed. Our results indicate that in the acute setting with no available microvascular expertise, DR of auricular avulsion injuries can be better than other nonmicrosurgical techniques in generating good esthetic results, especially in incomplete auricular avulsion and small segment avulsion. The operative approach depends on the clinical setting. DR of the auricular avulsion injuries is an accepted approach. It produces good cosmetic outcomes while preserving the auricular area for future reconstruction in case of re-attachment failure.

Keywords:

Direct attachment, ear amputation, ear avulsion, injury, review, surgery

Introduction

The prominent and exposed position of the ear increases its vulnerability to traumatic injuries. Traumatic ear avulsion (TEA) is relatively an infrequent event that may have tremendous psychological long-term consequences from the disfiguring deformity it entails. Reconstruction of traumatically amputated ear continues to be a major surgical challenge because of the complex shape, unique anatomical structure of the ear, and the small size of vessels responsible for its perfusion.^[1,2] Selection of the surgical procedure to reconstruct the traumatic avulsed ear is driven by several factors including the injury mechanism and extent, the patient's comorbidity, and the surgeon's

experience.^[3] The main goal is to achieve the best cosmetic result without destroying the periauricular area to allow future ear reconstruction in case of repair failure. Numerous repair techniques have been applied with variable success rates.

Microsurgical repair should be considered when suitable vessels for anastomosis are revealed on the initial examination. However, despite its superior esthetic outcome, microsurgical replantation is not possible in many hospitals, especially in middle- and low-income countries. The technical complexity of microvascular plantations necessitates on-site microvascular expertise, which is only available in specialized centers.^[4,5] Furthermore, it has other disadvantages including prolonged operative time, postoperative venous congestion, anemia

This is an open access journal, and articles are distributed under the terms of the Creative Commons Attribution-NonCommercial-ShareAlike 4.0 License, which allows others to remix, tweak, and build upon the work non-commercially, as long as appropriate credit is given and the new creations are licensed under the identical terms.

For reprints contact: WKHLRPMedknow_reprints@wolterskluwer.com

How to cite this article: Al-Ali MA, Abu-Zidan FM. Auricular avulsion injuries: Literature review and management algorithm. Turk J Emerg Med 2022;22:59-66.

Submitted: 26-11-2021

Accepted: 13-12-2021

Published: 11-04-2022

ORCID:

MAA: 0000-0002-4316-9485

FMA: 0000-0003-0143-8568

Address for correspondence:

Prof. Fikri M. Abu-Zidan,
Department of Surgery,
College of Medicine and
Health Sciences, UAE
University, Al-Ain, United
Arab Emirates.
E-mail: fabuzidan@uaeu.ac.ae

requiring repeated transfusion, and prolonged patient hospitalization. The practice of ear reconstruction using pocket principle and periauricular skin or fascia is discouraged by many authors.^[6-9] This is because it can result in cartilage resorption and fibrosis with a subsequently distorted auricle.

Despite the variability of different surgical approaches, there are no clear and proper guidelines to manage these injuries, which can be applied in both developed and developing countries. Direct re-attachment (DR) as a composite graft is a straightforward technique that can easily be performed in nonspecialized centers, especially in developing countries, under local anesthesia with a minimal hospital stay. However, there are no obvious indications on when to utilize the DR technique with TEA. We aimed to review the literature on surgical management of TEA with main focus on DR so as to develop a surgical management algorithm that can be applied in the absence of microsurgical facilities.

Methods

We have performed an extensive review of the relevant literature on papers indexed in PubMed describing TEA repaired with DR. Only papers in the English language were included and reviewed without restriction to a specific publication time window. We searched the database using the following keywords: "Amputation" or "avulsion" combined with "Ear," "Trauma," "Management," "Direct re-attachment," "Simple Replantation," and "Surgery." Our search was augmented by reviewing references of included articles. Only articles reporting on DR of the ear following complete and incomplete ear amputation were included.

Most of the published studies on DR of ear amputations were based on limited case series or reports. The following data were abstracted from the papers: demographic data, mechanism of trauma, degree of injury, presence of pedicle, ischemic time, type of anesthesia, adjuvant therapy, surgical outcome, and postoperative complications.

Results and Discussion

Classification of ear avulsion injuries

The wording and the meaning related to ear amputation vary in the literature and can be very ambiguous. Complete or total amputations are reserved solely for a complete separation of the ear.^[6,7] A complete avulsion of a smaller part of the pinna is described as partial avulsion.^[3,7] Cases of amputated auricles with narrow pedicle bridges were inconsistently expressed in the literature as incomplete, near-complete, subtotal avulsion, and extended or deep laceration.^[3,6,10,11] For

the purpose of this review, we are going to describe ear injuries as complete and incomplete avulsion.

Numerous classification systems of traumatic ear injuries are described in the literature. The most prevalent classification is anatomical. According to the involved anatomical regions, ear defects are classified into upper third, middle third, and lower third or any combinations.^[8,12]

Weerda^[13] proposed four degrees of ear injury severity. Cases with a first degree are characterized by abrasion with little cartilage involvement; the second-degree injury includes separation with an intact skin pedicle, the third degree is ear trauma involving avulsion with the existing amputated part, and the fourth degree is avulsion with a nonexisting segment.^[13]

Vascular anatomy of the auricle

The ear has a very distinctive anatomy. The auricle framework is created by the detailed architecture of the underlying cartilage that lacks internal circulation and its thin and highly vascularized soft tissue. These properties made the metabolic demands of the auricle relatively low. The anatomy of the arterial supply of the auricle is well demonstrated by Park and Roh.^[1] The perfusion of the auricle is mainly constituted by an arterial network originating from the superficial temporal artery (STA) and posterior auricular artery (PAA) with enormous well-developed interconnecting branches. The STA supplies the lateral surface of the auricle through the superior, middle, and inferior auricular branches. The PAA has a predictable course in the postauricular sulcus. Moreover, Park *et al.* demonstrated that perforating branches originating from the PAA, that come through the triangular fossa, the concha, and the earlobe, have a significant contribution to the vascularization of the anteroauricular surface of the auricle.^[14] Along the helical rim, the superior auricular artery supplies a vascular arcade that forms anastomotic connections between the anterior and posterior blood supplies by communicating with the PAA.^[2] This robust vascular anastomosis makes the auricle potentially well vascularized by one arterial system. The venous drainage of the auricle, which follows the arterial supply, is through the superficial temporal and postauricular veins that drain into the retromandibular and external jugular veins, respectively.^[15]

Surgical approaches

While numerous re-attachment approaches have been described, substantial controversy remains on managing these patients best in the acute setting. Presently, the most common re-attachment techniques include DR as a composite graft, microvascular replantation, pocket technique, and reconstruction using local flaps.

However, choosing among these repair methods can be challenging as they vary in technical demands, cosmetic results, and complications. Several factors influence decision-making when selecting the proper repair method of the auricular avulsion at the initial presentation in the acute care setting. These include the size and the condition of the avulsed segment, the status of the adjacent skin, the mechanism of injury, the patient's comorbidities, availability of microsurgical techniques, and the surgeon's experience.^[3,10]

Direct re-attachment

Re-attachment as a composite graft is a straightforward technique that requires short operative time and minimal hospital stay. A search of MEDLINE revealed 18 published papers with a total of 28 cases, 7 of which were complete ear amputations treated with direct surgical re-attachment [Tables 1 and 2]. The rarity of ear replantation is probably due to the low number of TEA cases in general.^[16]

Most of the reported cases were male (80.7%). The median (range) age of the patients was 33 (3–70) years. The mechanism of ear injury is an essential factor in determining the initial management approach. The most common mechanism of injury was cutting injury (44%), followed by motor vehicle injury (36%) and bite injuries from humans and animals (20%) [Tables 1 and 2]. DR is desired in relatively clean wounds due to sharp cuts and wounds with minimal crush injury and often leads to better surgical outcomes.^[5,9,17]

Incomplete ear avulsion

DR of an incomplete ear avulsion (IEA), where a narrow skin pedicle is preserved, can be safely performed with a good outcome.^[10,11,22,23] According to Erdmann *et al.*, an IEA can survive with DR as long as an attachment via the helical root is maintained.^[2]

Our analysis showed a total of 21 reported cases of IEA repaired with DR. The median (range) width of the skin pedicle bridge was 10 (3–30) mm with almost equally reported cases with superior and inferior skin pedicles [Figure 1]. General anesthesia was used in repairing 60% of incomplete auricular avulsion. However, local anesthesia can potentially damage the vessel at the pedicle site; therefore, it must be cautiously used.^[11]

As shown in Table 1, complications after DR of incomplete auricular avulsion were reported in nine (42.8%) cases. The most commonly observed complication was venous congestion in 5 patients, necrosis of the lobule in 3 patients, and necrosis of helical root in 2 patients. All cases reported in the literature have achieved satisfactory clinical and esthetic outcomes except in one patient who

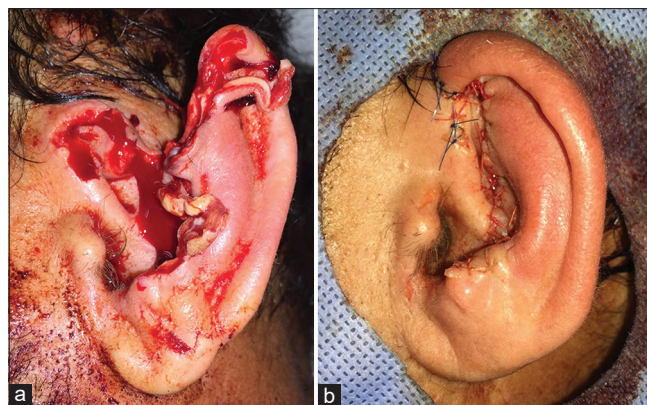


Figure 1: A 34-year-old man sustained injured by a large piece of glass that slipped on his head and sustained an incomplete amputation of his left ear. The ear remained attached by a 10-mm strip of skin at the level of the tragus (a). Direct postoperative view following a three-layer direct re-attachment of the ear (b). The patient developed ear edema which subsided and the ear survived (Courtesy of Dr. Mauro D'Arcangelo, Consultant Plastic Surgeon, Tawam Hospital, Al-Ain, United Arab Emirates)

required a secondary reconstruction of the lobule using a local flap [Figure 2].^[20]

Complete ear avulsion

Literature describing successful replantation of complete ear avulsion is exceptionally sparse. McDowell reported the first case of successful auricular composite graft replantation in 1968.^[21] A total of seven cases of complete ear avulsion repaired by DR had been presented in the literature [Table 2]. With respect to the involved anatomical region, the uppermost two-third was the most affected by the traumatic injury in 57%.

The surgeon can choose DR of the ear when microsurgical replantation is not possible. This also depends on the size of the amputated segment. DR of smaller segments is likely to have a greater chance for survival than larger segments. Repair of avulsion injuries smaller than 15 mm and those involving the earlobe can be achieved with DR.^[22,23] Steffen *et al.* expressed concerns about DR of segments larger than one-third of the auricle.^[6] Although the survival post DR as a composite graft is unpredictable, the approach is safe with low morbidity and preserves the postauricular skin intact. If successful, the technique would offer the best cosmetic result. If the composite graft failed, the postauricular skin would not be disturbed, jeopardizing future auricular reconstruction.^[6,24]

Rather than DR, some authors support the choice of delayed reconstruction with costal cartilage following primary closure if microvascular repair is not possible.^[9,25,26] If the avulsed ear is badly damaged, missing, or if the patient is unfit, primary closure of the defect with a secondary reconstruction can be a favorable option.^[3,9,13]

Table 1: Summary of reported cases in the literature of incomplete ear amputations managed with direct re-attachment

Author	Reference	Year	Number of cases	Age (year)	Sex	MOI	Pedicle site	Pedicle width (mm)	Anesthesia Adjuvant	Ear outcome	Complication
Clodius	[27]	1968	2	ND	ND	ND	Superior in 1 patient, inferior in 1 patient	30, 30	Local hyperthermia, anticoagulant	Survived	None
Bernstein and Nelson	[31]	1982	1	28	1 female	Animal bite	Superior	10	LA	Survived	Venous congestion
Safak and Kayikcioglu	[20]	1998	1	40	1 male	MVA	Superior	3	ND	Survived	Small necrotic lobule
Yotsuyanagi et al.	[17]	2001	1	42	1 female	Cutting injury	Superior	10	LA	Survived	None
Komorowska-Timek and Hardesty	[32]	2008	1	35	1 male	MVA	Superior and inferior	4, 7	GA	Survived	Venous congestion and small necrosis of helical root
Erdmann et al.	[2]	2009	3	23, 3, 52	2 males, 1 female	MVA in 1 patient, cutting injury in 2 patients	Superior	15, 10, 5	ND	Survived	Venous congestion in 2 patients, unhealed lobule in 1 patient
Ozçelik et al.	[11]	2009	1	36	1 male	MVA	Superior	6	GA	Survived	None
Bada and Pope	[19]	2013	1	4	1 male	Animal bite	Inferior	30	GA	Survived	Small necrotic area of the helix
Aremu	[18]	2014	3	12, 31, 45	3 males	MVA in 1 patient, cutting injury in 1 patient, human bite in 1 patient	Superior in 2 patients, inferior in 1 patient	20	2 GA, 1 LA	Survived	None
Kemaloğlu et al.	[30]	2015	1	57	1 male	Cutting injury	Inferior	5	GA	Survived	Venous congestion
Zhang et al.	[24]	2018	1	16	1 male	Cutting injury	Inferior	5, 3	LA	Survived	None
D'Arcangelo et al.	[10]	2020	5	34, 31, 50, 34, 32	5 males	MVA in 3 patients, cutting injury in 2 patients	Superior in 1 patient, inferior in 3 patients, both in 1 patient	7, 25, 25, 10	3 GA, 2 LA	Survived	Necrotic area of the lobule in 1 patient

GA: General anesthesia, HBOT: Hyperbaric oxygen therapy, LA: Local anesthesia, MVA: Motor vehicle accident, MOI: Mechanism of injury, ND: Not documented

The mean (range) ischemic time was 5 (0.5–8) h. Given the low metabolic demand of the auricle, ischemic time was not found to play an essential role in ear survival.^[13,27,28] Shelley *et al.* reported a successful auricular replantation 33 h following auricular avulsion.^[28] All reported cases of CEA, but one^[29] survived and showed a complete recovery. As with incomplete ear avulsion, the most common surgical complication among this group was venous congestion, observed in 5 (71%) patients [Figure 3]. A developed algorithm for surgical management of TEA injuries in acute settings based on available evidence from available literature is shown in Figure 4.

The addition of postoperative adjuvant therapy could augment the success rate of ear re-attachment by enhancing tissue perfusion.^[10,11,24,30] A variety of postoperative treatments have been described in the literature. However, there is no consensus on the

preference of one therapy over the other. Applied therapies included administration of anticoagulants, aspirin, dextran-40, Vitamin E, cooling, leeches, and hyperbaric oxygen therapy (HBOT).^[24,27,30,31] Our analysis has shown that the most commonly applied adjunct therapies were anticoagulants, followed by HBOT, and leeches, as shown in Tables 1 and 2.

Leeches application, alone or combined with anticoagulants, is used by many surgeons after ear replantation to relieve venous congestion by increasing the outflow.^[2,32,33] Other alternative methods include repeated stab incisions and anticoagulation such as systemic heparin, aspirin, and dextran-40.^[10,23,24] Although its exact mechanism of action is still not entirely understood, the role of HBOT in improving the clinical

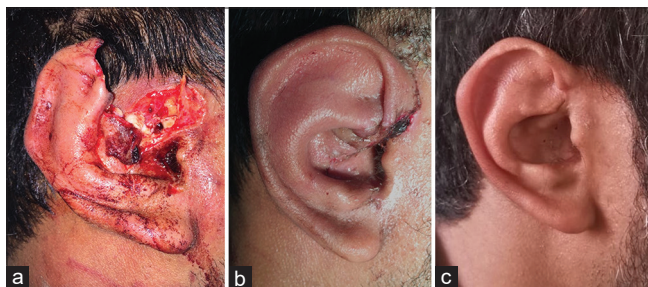


Figure 2: A 31-year-old man sustained an incomplete right ear amputation following a quad bike accident (a). The ear appeared well perfused 7 days post direct re-attachment (b). Two-year postoperative view with essentially healthy appearance of the ear (c) (Courtesy of Dr. Mauro D’Arcangelo, Consultant Plastic Surgeon, Tawam Hospital, Al-Ain, United Arab Emirates)

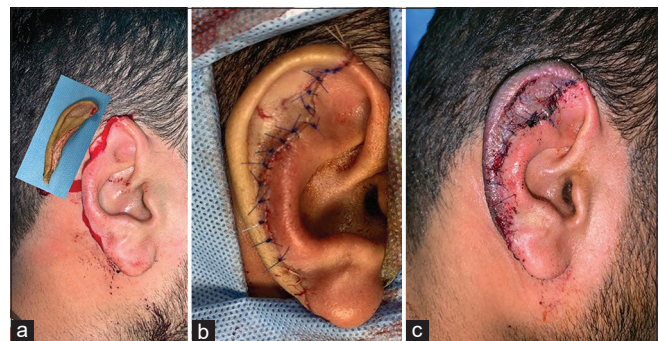


Figure 3: A 25-year-old man sustained a complete amputation of the upper third of the right ear involving the entire helix after being assaulted and bitten by another man; the amputated segment is shown after 1 h of separation from the body (a). Direct postoperative view following re-attachment of the ear (b). On postoperative day 4, the replanted ear appeared well perfused, bleeding at needle prick, and persistent venous congestion (c) (Courtesy of Dr. Mauro D’Arcangelo, Consultant Plastic Surgeon, Tawam Hospital, Al-Ain, United Arab Emirates)

Table 2: Summary of reported cases in the literature of complete ear amputations managed with direct re-attachment

Author	Reference	Year	Number of cases	Age (year)	Sex	MOI	Anatomical region	Ischemic time (h)	Anesthesia	Adjuvant	Ear outcome	Complication
Mcdowell	[21]	1971	1	15	Male	MVA	Upper 2/3	ND	ND	None	Survived	Small wedge defect
Lewis and Fowler	[23]	1979	2	46, 14	Female and male	Animal bite, cutting injury	Upper 1/3, Lower 1/3	0.5, 5	LA and GA	Cold compress, dextran-40	Survived	Venous congestion
Godwin <i>et al.</i>	[33]	1999	1	37	Male	ND	Upper 2/3	4	LA	Warm room, leeches	Survived	Venous congestion
Kalus	[35]	2014	1	18	Female	Cutting injury	Upper 2/3	7.5	ND	HBOT, cooling	Survived	Venous congestion, small contour defect
Brockhoff and Zide	[29]	2014	1	22	Male	Human bite	Lower 2/3	8	LA	None	Completely necrosed	Necrosis
Lee <i>et al.</i>	[25]	2017	1	70	Male	Cutting injury	Upper 2/3	ND	LA	HBOT, PRP, PDRN	Survived	Venous congestion, small eschar

GA: General anesthesia, HBOT: Hyperbaric oxygen therapy, LA: Local anesthesia, MVA: Motor vehicle accident, MOI: Mechanism of injury, ND: Not documented, PRP: Platelet-rich plasma, PDRN: Polydeoxyribonucleotide

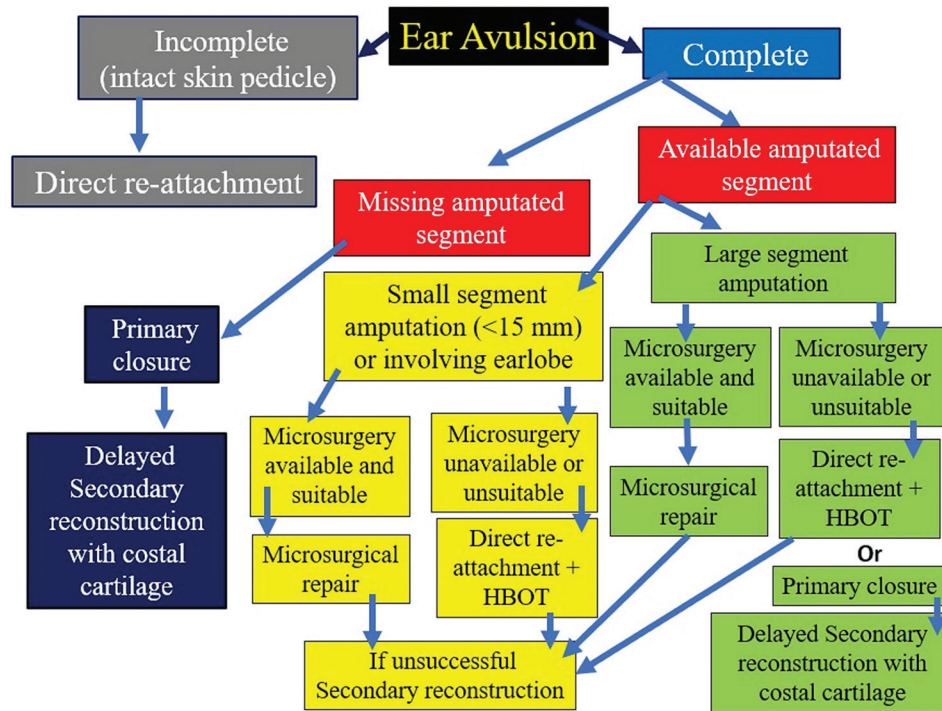


Figure 4: A developed algorithm for surgical management of traumatic auricular avulsion injuries in the acute settings depending on the degree of the avulsion, size of the amputated segment, and availability of microsurgery facility and expertise. HBOT: Hyperbaric oxygen therapy

outcome following auricular replantation is overlooked. It has been shown that HBOT enhances oxygen delivery, increases neovascularization, stimulates granulation tissue formation, and reduces tissue edema.^[34,35] In both an animal experimental model study and human cases, data suggest a benefit of HBO therapy to the survival of the re-attached auricular composite graft, even with large segment avulsion.^[25,34,35] Furthermore, this treatment has demonstrated successful effects in minimizing the necrosis of pedicled flaps.^[36,37]

Microsurgical repair

Although it yields the best cosmetic outcome, microvascular replantation of an amputated ear segment may not be an available or appropriate option for all patients.^[5,6] This approach should be attempted when the facility can handle microsurgical repair, suitable vessels are identified on initial examination, and the amputated segment is repairable. Furthermore, the patient should be adequately counseled about the possible complications and expected postoperative care. Preferably, venous anastomosis is achieved, but this will not be possible in most cases because of a lack of appropriately sized veins.^[4,34,38] The first successful clinical microvascular replantation of a completely amputated ear was reported in 1980 by Pennington *et al.* using the vein grafts from the superficial temporal vessels.^[39] Ever since, many authors have replicated the approach and a variety of technological advancements have been suggested.^[4,5,28,40]

The most common complication associated with microvascular replantation of the auricle is venous congestion which, in many cases, can lead to complete loss of the ear segment.^[4,5] Venous congestion can be dealt with using leach therapy, skin puncture of the replanted segment, and anticoagulation.^[4,40]

Microsurgical replantation has some disadvantages; it requires longer operative time and hospital stay, multiple blood transfusions, and has a significant failure rate.^[4] The average operative time reported by Kind was 6 h, with an average hospital stay of 11.4 days.^[16] Nevertheless, the technique offers the best cosmetic outcome when successful revascularization is achieved.^[6,16,40]

Other techniques

Various other nonmicrosurgical techniques have been described in the literature, including the pocket method, local flap reconstruction, and temporoparietal fascia (TPF) flap reconstruction. Studies showed that techniques utilizing periauricular skin or fascia flaps would result in auricular shrinkage and distortion due to cartilage resorption.^[6,9] The principle of the retroauricular pocket was first proposed in 1971 by Mladick *et al.*^[41] The method is a two-step technique that involves removing the skin of the amputated segment followed by re-attachment to the stump and then burial in a retroauricular pocket. In this way, a greater contact surface with the vascular bed is created to enhance

the probability of graft “take.” A second procedure is required after 28 days to remove the ear from the pocket.^[41]

The TPF flap is another nonmicrosurgical technique that provides a vascularized flap, based on STA and vein, to an amputated auricle. The skin of the amputated part is first removed, preserving an intact perichondrium, suturing the cartilage to the stump, applying a TPF flap, followed by covering the area with a skin graft.^[42,43] Steffen *et al.* supported renouncing methods using pocket technique and periauricular tissue flaps because of the inevitable cartilaginous distortion.^[6,40] In addition, these methods cause additional trauma to the ear remnant and the surrounding tissue, jeopardizing their use for future secondary reconstruction.^[6,7,9]

Limitations

It is important to note that this review has certain limitations. Most of the studies were retrospective and had a small number of patients. They showed good and promising results as authors tend to report their successful cases rather than failed attempts of replantation, which resembles selection bias. This resulted in a small number of reported cases as well as a high probability of publication bias. Hence, it is difficult to compare outcomes and estimate the failure rate of the surgical techniques. Furthermore, certain variables were not reported in some articles.

Conclusions

The optimum management of auricular avulsion injuries in acute settings is a continued therapeutic dilemma. The surgeon’s choice of operative approach is dependent on the situation found at the initial presentation and the facilities available. Even in low-income countries, DR of the auricular avulsion injuries could be tried. It produces good cosmetic outcomes while preserving the auricular area for future ear reconstruction in case of re-attachment failure. The success rate of direct replantation could be augmented by applying postoperative adjuvant therapies such as HBOT if available. Further multicentric clinical studies are required to demonstrate the effectiveness of different postoperative adjuvant therapies and assess long-term patient satisfaction with the outcome.

Acknowledgments

The authors thank Dr. Mauro D’Arcangelo, Consultant Plastic Surgeon, Tawam Hospital, Al-Ain, United Arab Emirates, for kindly supplying us with the clinical images.

Author contribution statement

MAA and FAZ contributed to the study conception, design, and structure; MAA searched, collected, and critically read the literature; MAA drafted the first version of the manuscript; FAZ critically revised and edited the manuscript; all authors read and approved the final version of the manuscript.

Conflicts of interest

None Declared.

Ethics approval

Data of the review are public published data. The study does not require ethical approval.

Consent to participate

Written informed consent was taken from the patients to publish their clinical images.

Funding

None.

References

1. Park C, Roh TS. Anatomy and embryology of the external ear and their clinical correlation. *Clin Plast Surg* 2002;29:155-74.
2. Erdmann D, Bruno AD, Follmar KE, Stokes TH, Gonyon DL, Marcus JR. The helical arcade: Anatomic basis for survival in near-total ear avulsion. *J Craniofac Surg* 2009;20:245-8.
3. Steffen A, Frenzel H. Trauma management of the auricle. *Facial Plast Surg* 2015;31:382-5.
4. Kind GM, Buncke GM, Placik OJ, Jansen DA, D’Amore T, Buncke HJ Jr. Total ear replantation. *Plast Reconstr Surg* 1997;99:1858-67.
5. Jung SW, Lee J, Oh SJ, Koh SH, Chung CH, Lee JW. A review of microvascular ear replantation. *J Reconstr Microsurg* 2013;29:181-8.
6. Steffen A, Katzbach R, Klaiber S. A comparison of ear re-attachment methods: A review of 25 years since Pennington. *Plast Reconstr Surg* 2006;118:1358-64.
7. Gailey AD, Farquhar D, Clark JM, Shockley WW. Auricular avulsion injuries and re-attachment techniques: A systematic review. *Laryngoscope Investig Otolaryngol* 2020;5:381-9.
8. Li D, Xu F, Zhang R, Zhang Q, Xu Z, Li Y, *et al.* Surgical reconstruction of traumatic partial ear defects based on a novel classification of defect sizes and surrounding skin conditions. *Plast Reconstr Surg* 2016;138:307e-316e.
9. Pearl RA, Sabbagh W. Reconstruction following traumatic partial amputation of the ear. *Plast Reconstr Surg* 2011;127:621-9.
10. D’Arcangelo M, Al-Ali MA, Abu-Zidan FM. Primary re-attachment of near-complete ear amputation: A successful outcome. *Ear Nose Throat J* 2020 Dec15:145561320982170.
11. Özçelik D, Unveren T, Toplu G. Subtotal ear amputation with a very narrow pedicle: A case report and review of the literature. *Ulus Travma Acil Cerrahi Derg* 2009;15:306-10.
12. Kolodzynski MN, Kon M, Egger S, Breugem CC. Mechanisms of ear trauma and reconstructive techniques in 105 consecutive patients. *Eur Arch Otorhinolaryngol* 2017;274:723-8.
13. Weerden H. *Surgery of the Auricle: Tumors-Trauma-Defects-Abnormalities*. New York: Thieme; 2007. p. 314.
14. Park C, Lineaweaver WC, Rumly TO, Buncke HJ. Arterial supply of the anterior ear. *Plast Reconstr Surg* 1992;90:38-44.
15. Germann AM, Jamal Z, Al Khalili Y. Anatomy, head and neck, scalp veins. In: *StatPearls*. Treasure Island (FL): StatPearls Publishing, Copyright © 2021, StatPearls Publishing LLC.; 2021.
16. Kind GM. Microvascular ear replantation. *Clin Plast Surg* 2002;29:233-48, vii.
17. Yotsuyanagi T, Yamashita K, Watanabe Y, Urushidate S, Yokoi K, Sawada Y. Reconstruction of a subtotally amputated auricle: A case report. *Scand J Plast Reconstr Surg Hand Surg* 2001;35:425-8.
18. Aremu SK. Nonmicroscopic reconstruction of subtotally amputated/torn auricles: Report of 3 cases. *Ear Nose Throat J* 2014;93:E1-3.
19. Bada AM, Pope GH. Use of hyperbaric oxygen as adjunct in salvage of near-complete ear amputation. *Plast Reconstr Surg*

- Glob Open 2013;1:e1-5.
20. Safak T, Kayikcioglu A. A traumatic ear amputation attached with a narrow pedicle. *Ann Plast Surg* 1998;40:106-7.
 21. McDowell F. Successful replantation of a severed half ear. *Plast Reconstr Surg* 1971;48:281-3.
 22. Ihrari T, Balaguer T, Monteil MC, Chignon-Sicard B, Médard de Chardon V, Riah Y, et al. Surgical management of traumatic ear amputations: Literature review. *Ann Chir Plast Esthet* 2009;54:146-51.
 23. Lewis EC 2nd, Fowler JR. Two replantations of severed ear parts. *Plast Reconstr Surg* 1979;64:703-5.
 24. Zhang C, Teng L, Xu JJ, Lu JJ, Xie F, Yang LY, et al. Incomplete ear amputation. *J Craniofac Surg* 2018;29:2231-3.
 25. Lee SK, Lim YM, Lew DH, Song SY. Salvage of unilateral complete ear amputation with continuous local hyperbaric oxygen, platelet-rich plasma and polydeoxyribonucleotide without micro-revascularization. *Arch Plast Surg* 2017;44:554-8.
 26. Brunelli A, Bottini DJ, Cervelli V, Cervelli G, Grimaldi M. Reconstruction of partially amputated external ear with costal cartilage graft: Case report. *Acta Otorhinolaryngol Ital* 2004;24:150-6.
 27. Clodius L. Local hypothermia for the avulsed external ear. *Br J Plast Surg* 1968;21:250-2.
 28. Shelley OP, Villafane O, Watson SB. Successful partial ear replantation after prolonged ischaemia time. *Br J Plast Surg* 2000;53:76-7.
 29. Brockhoff HC 2nd, Zide M. Delayed ear reconstruction: Case report of reconstruction of an avulsed ear 2 days after injury. *J Oral Maxillofac Surg* 2014;72:4.e1-4.
 30. Kemaloglu CA, Kılıç F, Günay GK. Reconstruction of a subtotally amputated auricle with a very narrow inferior pedicle. *Case Reports Plast Surg Hand Surg* 2015;2:77-9.
 31. Bernstein L, Nelson RH. Replanting the severed auricle. An update. *Arch Otolaryngol* 1982;108:587-90.
 32. Komorowska-Timek E, Hardesty RA. Successful re-attachment of a nearly amputated ear without microsurgery. *Plast Reconstr Surg* 2008;121:165e-9e.
 33. Godwin Y, Allison K, Waters R. Reconstruction of a large defect of the ear using a composite graft following a human bite injury. *Br J Plast Surg* 1999;52:152-4.
 35. Kalus R. Successful bilateral composite ear re-attachment. *Plast Reconstr Surg Glob Open* 2014;2:e174.
 34. McClane S, Renner G, Bell PL, Early EK, Shaw B. Pilot study to evaluate the efficacy of hyperbaric oxygen therapy in improving the survival of reattached auricular composite grafts in the New Zealand White rabbit. *Otolaryngol Head Neck Surg* 2000;123:539-42.
 36. Ulkür E, Yüksel F, Açikel C, Celiköz B. Effect of hyperbaric oxygen on pedicle flaps with compromised circulation. *Microsurgery* 2002;22:16-20.
 37. Richards L, Lineaweaver WC, Stile F, Zhang J, Zhang F. Effect of hyperbaric oxygen therapy on the tubed pedicle flap survival in a rat model. *Ann Plast Surg* 2003;50:51-6.
 38. Safak T, Ozcan G, Keçik A, Gürsu G. Microvascular ear replantation with no vein anastomosis. *Plast Reconstr Surg* 1993;92:945-8.
 39. Pennington DG, Lai MF, Pelly AD. Successful replantation of a completely avulsed ear by microvascular anastomosis. *Plast Reconstr Surg* 1980;65:820-3.
 40. Lin PY, Chiang YC, Hsieh CH, Jeng SF. Microsurgical replantation and salvage procedures in traumatic ear amputation. *J Trauma* 2010;69:E15-9.
 41. Mladick RA, Horton CE, Adamson JE, Cohen BI. The pocket principle: A new technique for the re-attachment of a severed ear part. *Plast Reconstr Surg* 1971;48:219-23.
 42. Saad Ibrahim SM, Zidan A, Madani S. Totally avulsed ear: New technique of immediate ear reconstruction. *J Plast Reconstr Aesthet Surg* 2008;61 Suppl 1:S29-36.
 43. Abd-Almuktader MA. Nonmicrosurgical single-stage auricular replantation of amputated ear. *Ann Plast Surg* 2011;67:40-3.