



Access this article online

Quick Response Code:



Website:

www.turkjemergmed.org

DOI:

10.4103/2452-2473.320803

Case Report

Medical treatment for paradoxical and saddle pulmonary embolism in a young man with patent foramen ovale and coronavirus disease 2019

Amir Behnam Kharazmi¹, Sahar Mirbaha², Hamidreza Hatamabadi³,
Fatemeh Shojaeian⁴, Fatemeh Omid^{5*}

¹Department of Internal Medicine, Imam Hossein Hospital, Shahid Beheshti University of Medical Sciences, ²Department of Emergency Medicine, Shohadaye Tajrish Hospital, Shahid Beheshti University of Medical Sciences, ³Department of Emergency Medicine, Imam Hossein Hospital, Shahid Beheshti University of Medical Sciences, ⁴Department of Medicine, Shahid Beheshti University of Medical Sciences, ⁵Department of Cardiology, School of Medicine, Imam Hossein Hospital, Shahid Beheshti University of Medical Sciences, Tehran, Iran *Corresponding author

Abstract:

Here, we reported a 32-year-old male presenting to the emergency department with respiratory symptoms and coronavirus disease 2019 (COVID-19) diagnosis. Multiple thrombi were detected in his heart and inferior vena cava, probably due to former deep-vein thrombosis. The presence of patent foramen ovale and high pressure of the right heart caused the clots to enter the heart's left side. He received fibrinolytics, and his condition improved with no need for surgery. Hence, patients with impending paradoxical embolism may take advantage of medical treatment, such as fibrinolytics. Moreover, COVID-19 appears to be associated with a strong thrombotic tendency, and anticoagulants might be helpful.

Keywords:

Case report, coronavirus disease 2019, fibrinolytic therapy, impending paradoxical embolism, massive pulmonary emboli

Introduction

Impending paradoxical embolism (IPE), a thrombus straddling patent foramen ovale (PFO) or moving paradoxical embolism, is a rare condition that occurs when a clot, usually a lower extremity deep-vein thrombus, reaches the heart and is trapped in a PFO or an atrial septal defect in the absence of systemic embolization.^[1] PFO usually results in a left-to-right shunt between the atria. However, massive pulmonary thromboembolism (PTE) could raise the pulmonary artery pressure, reversing the

gradient. Hence, clots could pass across the PFO to the left atrium, resulting in paradoxical systemic embolization, with the larger ones trapped in the foramen, inducing IPE.^[2,3] They might have various clinical manifestations, the most important of which is cryptogenic stroke; however, most patients are asymptomatic.^[2]

In coronavirus disease 2019 (COVID-19), over-activation of the immune system results in a cytokine storm.^[4] Moreover, local thrombotic stimulation of smooth muscle cells in the artery might result in an amplified inflammatory response, causing a rise in inflammatory marker levels and a

This is an open access journal, and articles are distributed under the terms of the Creative Commons Attribution-NonCommercial-ShareAlike 4.0 License, which allows others to remix, tweak, and build upon the work non-commercially, as long as appropriate credit is given and the new creations are licensed under the identical terms.

For reprints contact: WKHLRPMedknow_reprints@wolterskluwer.com

How to cite this article: Kharazmi AB, Mirbaha S, Hatamabadi H, Shojaeian F, Omid F. Medical treatment for paradoxical and saddle pulmonary embolism in a young man with patent foramen ovale and coronavirus disease 2019. *Turk J Emerg Med* 2021;21:133-6.

Submitted: 10-02-2021

Revised: 25-03-2021

Accepted: 06-04-2021

Published: 07-07-2021

ORCID:

ABK: 0000-0003-1192-4893

SM: 0000-0002-8416-754X

HH: 0000-0002-9085-8806

FS: 0000-0001-5972-9953

FO: 0000-0001-7302-9136

Address for correspondence:

Prof. Fatemeh Omid,
Department of Cardiology,
School of Medicine, Imam
Hossein Hospital, Shahid
Beheshti University of
Medical Sciences, Tehran,
Iran.
E-mail: dr.fateme.omidi@gmail.com

systemic procoagulant effect.^[5,6] In patients with lung involvement, segmental and sub-segmental arteries of consolidated areas might be involved in PTE due to pulmonary artery thrombosis as a side effect of severe lung inflammation and hypercoagulability.^[7] It also occurs due to the cytokine storm in the recovery phase, mostly in severe cases.^[5,8,9] Furthermore, local inflammation, hemodynamic changes, and the induction of procoagulant factors driven by the enhanced systemic proinflammatory response might result in a higher risk of thromboembolic complications in severe cases.^[10] However, to the best of our knowledge, PTE has not manifested as an initial symptom and is not used for COVID-19 diagnosis. Our patient presented with respiratory symptoms, previous COVID-19 involvement, and thrombosis in his heart, lung, and inferior vena cava, with the presence of PFO and IPE.

Case Report

A 32-year-old man was referred to the emergency department, complaining of dyspnea, chest discomfort, and recurrent exercise-related syncope in the past 2 days. He suffered from fever, dry cough, and mild watery diarrhea during the previous 3 weeks, and symptomatic treatments improved the patient's condition. His medical history and family history were unremarkable. On initial physical examination, the patient had a blood pressure (BP) of 90/50 mmHg, O₂ saturation (O₂ sat) of 85% and 93% (with mask reservoir), a pulse rate (PR) of 120/min, a respiratory rate (RR) of 25/min, and a temperature (T) of 36.7°C. He appeared ill but was conscious, showed no sign of central or peripheral cyanosis. Findings on pulmonary examination were nonsignificant, except for tachypnea and his cardiac auscultation was normal. In his lower extremities, there was no size difference, pain, edema, or heat.

He was transferred to the intensive care unit, while his electrocardiogram showed sinus tachycardia. Bedside transthoracic echocardiography (TTE) was performed (BP = 90/60 mmHg): normal left ventricle (LV) size, mild LV systolic dysfunction, and a global ejection fraction (EF) of about 45%–50%. There was paradoxical septal motion due to right ventricle (RV) pressure overload, severe RV dilation (mid-diameter = 44 mm), severe RV systolic dysfunction, moderate right atrial (RA) enlargement, moderate-to-severe tricuspid regurgitation (TR), with a TR gradient of about 54 mmHg. Systolic pulmonary arterial hypertension at rest (SPAP = 69 mmHg) was noted. A large hypermobile elongated mass straddling the interarterial septum suggested a thrombus in transit, which protruded to LV and RV during diastole. Fixed and dilated inferior vena cava (IVC) (size = 26 mm) was also observed with a fixed clot attached to its posterior wall.

The patient underwent intravenous thrombolytic therapy, receiving recombinant tissue plasminogen activator (Actilyse, Boehringer Ingelheim Co., Germany) at a dose of 100 mg in 2 h. When his partial thromboplastin time reached twice the standard value, he received a single heparin dose of 5000 IU/mL, followed by 1000 IU/mL/h intravenously. After 12 h of fibrinolytic therapy, another TTE was performed with the following results: LV size was normal with a global EF of about 50%. RV size was normal with mild RV systolic dysfunction, and there was mild-to-moderate TR with SPAP of about 25 mmHg. No mass or clot was noted in cardiac chambers. In the four-chamber view of TTE [Figure 1a], RV appeared strained and dilated, and the septum deviated toward LV. A clot was noted in LV, moving in systole and diastole with the mitral valve. A similar echo was seen in RV, and both clots moved simultaneously. In the Doppler view, a stream was noted between the two atria, raising the suspicion about a connection between the two sides of the heart [Figure 1a]. A pulmonary computed tomography angiogram showed a massive saddle embolism in the main trunk, in addition to the left and right branches of the pulmonary artery [Figure 1b]. Besides, necrosis of pulmonary parenchyma was visible at the periphery with evidence of parenchyma involvement as ground glass and crazy paving patterns in favor of COVID-19.

Approximately, 4 h after receiving the fibrinolytic agent, his vital signs improved significantly. On the next day, his O₂ sat increased to 97% with nasal oxygen, and his RR, systolic blood pressure, and PR were 18/min, 120 mmHg, and 100/min, respectively. From the 7th day

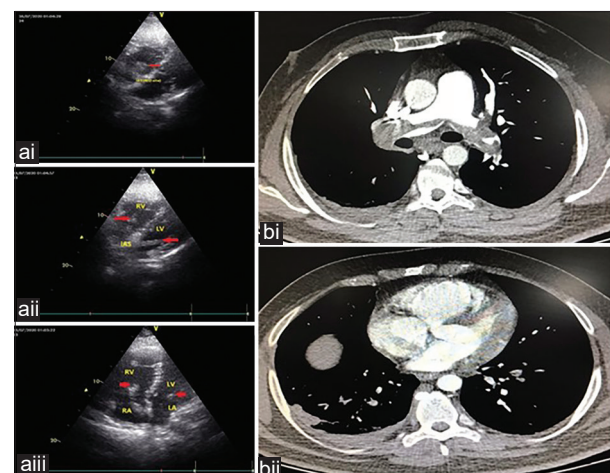


Figure 1: (ai) Subcostal view shows a protruding thrombus burden in left ventricle and right ventricle (arrows) during diastole. (aii) Modified subcostal view focused on inter-arterial septum shows redundant inter-arterial septum with elongated thrombus straddling the inter-arterial septum via patent foramen ovale. (aiii) Apical 4-chamber view demonstrates severe right ventricle and right atrial dilation; McConnell's sign is present, and arrows indicate a large thrombus burden in 4 chambers. (bi) Pulmonary computed tomography angiogram. (bii) A clot in patent foramen ovale

of admission, the patient's O₂ sat was normal without oxygen therapy. His COVID-19 nasal swab polymerase chain reaction test was negative, although his serology tests favored COVID-19 involvement [Table 1].

Considering the patient's critical situation, the treatment team decided not to perform cardiac surgery and instead prescribed a fibrinolytic agent. In this patient, IVC clots' presence suggested that it originated from thrombosis in former deep vein thrombosis (DVT), which reached the heart, increased its pressure, and then came across to the left side through the PFO. Finally, he was discharged with warfarin at a dose of 7.5 mg/daily. Three months later, he was given rivaroxaban at a dose of 15 mg/12 h for 3 weeks, followed by 20 mg/daily for another 3 months. His general condition is well, with no complaints. Informed consent was obtained from the patient, and confidentiality was confirmed.

Discussion

PTE is observed in COVID-19 patients after cytokine storm or in their recovery phase, but it is not an initial manifestation to the best of our knowledge; hence, it could not aid in the diagnosis. Moreover, most

Table 1: Patients' laboratory data

Lab test	Results	Normal range
Anti-SARS-COVID-2 (IgM) (index)	6.5	<0.98
Anti-SARS-COVID-2 (IgG) (index)	13.5	<0.98
RF-quantitative (IU/mL)	16	Up to 15
Lupus anticoagulant	Negative	-
IL-6 (pg/mL)	86.2	Up to 5.9
NT-PRO-BNP (pg/mL)	5493	<125
Protein S (go/mL)	Normal	-
Protein C (IU/dL)	Normal	-
Fibrinogen (mg/dL)	383	150-350
CPK (IU/L)	85	24-195
CRP-quantitative (mg/L)	4.7	Up to 5.9
PCR SARS-Cov-2	Not detected	-
C3 (mg/dL)	216.5	90-180
C4 (mg/dL)	54.4	20-50
CH50 (U/mL)	102	41.68-95.06
Cardiolipin Ab (IgM) (U/mL)	7	<12
Cardiolipin Ab (IgG) (U/mL)	2	<12
Anti-endomysial Ab (IgA) (titer)	1/10	<1/10
P-ANCA (Anti MPO) (U/mL)	4	<12
C-ANCA (PR3) (U/mL)	2	<12
Anti-ds DNA (IU/mL)	<10	<100
Anti CCP (U/mL)	3.1	<5
ANA (titer)	<1/100	<1/100

RF: Rheumatoid Factor. IL-6: Interleukin-6. NT-PRO-BNP: N-Terminal prohormone b-type natriuretic peptide, CPK: Creatine phosphokinase, CRP: C-reactive protein, Ab: Antibody, Anti CCP: Anti-cyclic citrullinated peptide, ANA: Antinuclear antibody, ANCA: Antineutrophil cytoplasmic antibodies, P-ANCA: Perinuclear ANCA, C-ANCA: Cytoplasmic ANCA, PCR: Polymerase chain reaction, SARS-Cov-2: Severe acute respiratory syndrome coronavirus 2, Anti-ds DNA: Anti-double stranded DNA, MPO: Myeloperoxidase

previously reported venous thromboembolism cases were in severely ill patients, following cytochemical storm syndrome development.^[10] With no history of cardiac failure, cardiac fibrillation, and myocardial infarction in this young patient, heart thrombosis would not form normally. The IVC thrombosis detected in transesophageal echocardiography suggested a previous DVT which resulted in PTE and pulmonary hypertension. This pulmonary hypertension caused the clots to enter the left heart through PFO.

Definite diagnosis of paradoxical embolism entails the detection of a RA thrombus crossing the foramen ovale.^[11] However, observation of this phenomenon during life is rare and is limited to the echocardiographic reports. The paradoxical embolism diagnosis is almost always presumptive in clinical practice and is made when an arterial thromboembolic event occurs in the absence of atrial fibrillation, cardiac diseases, or severe atherosclerosis of the thoracic aorta.^[12]

In this patient, the risk of other thromboembolic events, besides the pulmonary embolism, as a complication of the COVID-19 cytokine storm, was high due to PFO, which makes a shunt. Therefore, the importance of this rare and significant event should be recognized in patients with massive embolism and PFO, and it should be noted that they might benefit from medical treatment rather than surgery. Besides, COVID-19 appears to be associated with a strong thrombotic tendency and even massive PTE due to thrombo-inflammation, and physicians should consider anticoagulant prophylaxis even in outpatient cases of COVID-19.

Conclusion

A young patient with COVID-19 and IPE received fibrinolytic agents instead of surgical intervention. Although surgical intervention is the main treatment option in patients with paradoxical emboli, they might benefit from medical treatment.

Acknowledgment

We would like to thank Dr. Masoomeh Raoufi for obtaining the images and pictures presented in this case report.

Authors' contributions statement

F.O: conceived of the presented idea; AK, H.H and F.Sh.: wrote the manuscript in consultation with all authors; AK, S.M, and H.H: conceived the study and were in charge of overall direction and planning; AK, S.M, H.H, and F.O: were directly involved in the treatment plan of the patients; F.O has conducted the TTE and reported PCTA; All authors discussed the results and commented on the manuscript.

Consent for publication

Written informed consent was obtained from the patient for publication of this case report and any accompanying images. A copy of the written consent is available for review by the Editor-in-Chief of this journal.

Declaration of patient consent

The authors certify that they have obtained all appropriate patient consent forms. In the form, the patient has given his consent for his images and other clinical information to be reported in the journal. The patient understand that name and initials will not be published and due efforts will be made to conceal identity, but anonymity cannot be guaranteed.

Funding

None.

Conflicts of interest

None Declared.

References

1. Barbaryan A, Bailuc S, Abicht T, Barsamyan S, Gizaw Y, Mirrakhimov AE. Saddle Pulmonary embolus caught in transit across a patent foramen ovale. *Case Rep Pulmonol* 2019;2019:5747598.
2. Hagen PT, Scholz DG, Edwards WD. Incidence and size of patent foramen ovale during the first 10 decades of life: An autopsy study of 965 normal hearts. *Mayo Clin Proc* 1984;59:17-20.
3. Chan FP, Jones TR. Images in clinical medicine. Paradoxical embolus. *N Engl J Med* 2001;345:803.
4. Sarzi-Puttini P, Giorgi V, Sirotti S, Marotto D, Ardizzone S, Rizzardini G, *et al.* COVID-19, cytokines and immunosuppression: What can we learn from severe acute respiratory syndrome? *Clin Exp Rheumatol* 2020;38:337-42.
5. Tang N, Bai H, Chen X, Gong J, Li D, Sun Z. Anticoagulant treatment is associated with decreased mortality in severe coronavirus disease 2019 patients with coagulopathy. *J Thromb Haemost* 2020;18:1094-9.
6. Lin L, Lu L, Cao W, Li T. Hypothesis for potential pathogenesis of SARS-CoV-2 infection-A review of immune changes in patients with viral pneumonia. *Emerg Microbes Infect* 2020;9:727-32.
7. Cavagna E, Muratore F, Ferrari F. Pulmonary Thromboembolism in COVID-19: Venous thromboembolism or arterial thrombosis? *Radiol Cardiothorac Imaging* 2020;2:e200289.
8. Griffin DO, Jensen A, Khan M, Chin J, Chin K, Saad J, *et al.* Pulmonary embolism and increased levels of d-dimer in patients with coronavirus disease. *Emerg Infect Dis* 2020;26:1941-3.
9. Zhang L, Yan X, Fan Q, Liu H, Liu X, Liu Z, *et al.* D-dimer levels on admission to predict in-hospital mortality in patients with Covid-19. *J Thromb Haemost* 2020;18:1324-9.
10. Guillén L, Telenti G, Botella Á, Masiá M. Dyspnea and pleuritic chest pain during the COVID-19 pandemic. *Enferm Infecc Microbiol Clin* 2021;39:41-2.
11. Thompson T, Evans W. Paradoxical embolism. *QJM An Int J Med* 1930;135-50.
12. Konstantinides S, Geibel A, Kasper W, Olschewski M, Blümel L, Just H. Patent foramen ovale is an important predictor of adverse outcome in patients with major pulmonary embolism. *Circulation* 1998;97:1946-51.