

# Successful Outcome of Mediastinitis After 26 Days Delay in Diagnosis

## Başarıyla Sonuçlanan 26 Gün Geç Tanı Almış Mediastinit Olgusu

Farid Effekhari MILANI, Samad SHAMS VAHDATI, Pouya PAKNEJAD

Department of Emergency Medicine, Imam Reza Hospital, Tabriz, Iran

### SUMMARY

Acute mediastinitis, which is characterized by inflammation of thoracic tissues, is a life-threatening infection and a surgical emergency. The mortality rate for this ailment is reported between 14-42%, which makes it important to diagnose and treat as soon as possible. We presented and discussed a case of a 38-year-old male patient with blunt trauma to the chest and back from falling who reported to the emergency department after 26 days with severe chest pain and a toxic condition. He underwent an anterolateral thoracotomy and several rounds of pleural flushing; ultimately, he survived.

**Key words:** Infection; mediastinitis; trauma.

### ÖZET

Akut mediastinit, torasik dokuların iltihabı olarak, hayatı tehdit eden bir enfeksiyon ve cerrahi acildir. Ölüm oranı %14 ile 42 arasında bildirilmektedir. Akut mediastinitin en kısa zamanda tanınması ve tedavisi önemlidir. Bu yazıda, düşmeye bağlı künt göğüs ve sırt travması olan ve 26 gün sonra acil servise ciddi göğüs ağrısı ve toksik durumda başvuran 38 yaşında erkek olguyu sunduk ve tartıştık. Hastaya anterolateral torakotomi ve birkaç kez plevral yıkama yapıldı ve sonuçta hasta hayatta kalabildi.

**Anahtar sözcükler:** Enfeksiyon; mediastinit; travma.

### Introduction

Mediastinitis is a severe, life-threatening condition and a surgical emergency that arises as a complication of thoracic surgery, oropharyngeal infection, or after neck and chest trauma. Mediastinitis has a mortality rate between 14% and 42%.<sup>[1]</sup> Early diagnosis and treatment can minimize mortality,<sup>[2]</sup> while delays in treatment increase rates of mortality.<sup>[3]</sup> We report and discuss a 38-year-old male patient with mediastinitis, which occurred due to trauma.

### Case Report

A 38-year-old man presented to the emergency department

(ED) of Imam Reza hospital with neck and back pain after a trauma due to falling down 3 meters. Physical exams and neck and chest X-rays (CXR) were normal and chest magnetic resonance imaging (MRI) did not show any neurological damage. Patient was discharged from ED with stable vital signs and analgesic drugs.

Two weeks later he was admitted again in ED with a complaint of pain in sternum. Due to normal chest X-Ray (Figure 1a) and electrocardiogram (ECG), physicians came to the conclusion that the pain had been caused by heavy physical activity. Patient was discharged with analgesics.

Twenty-six days later, the patient was brought to the ED with

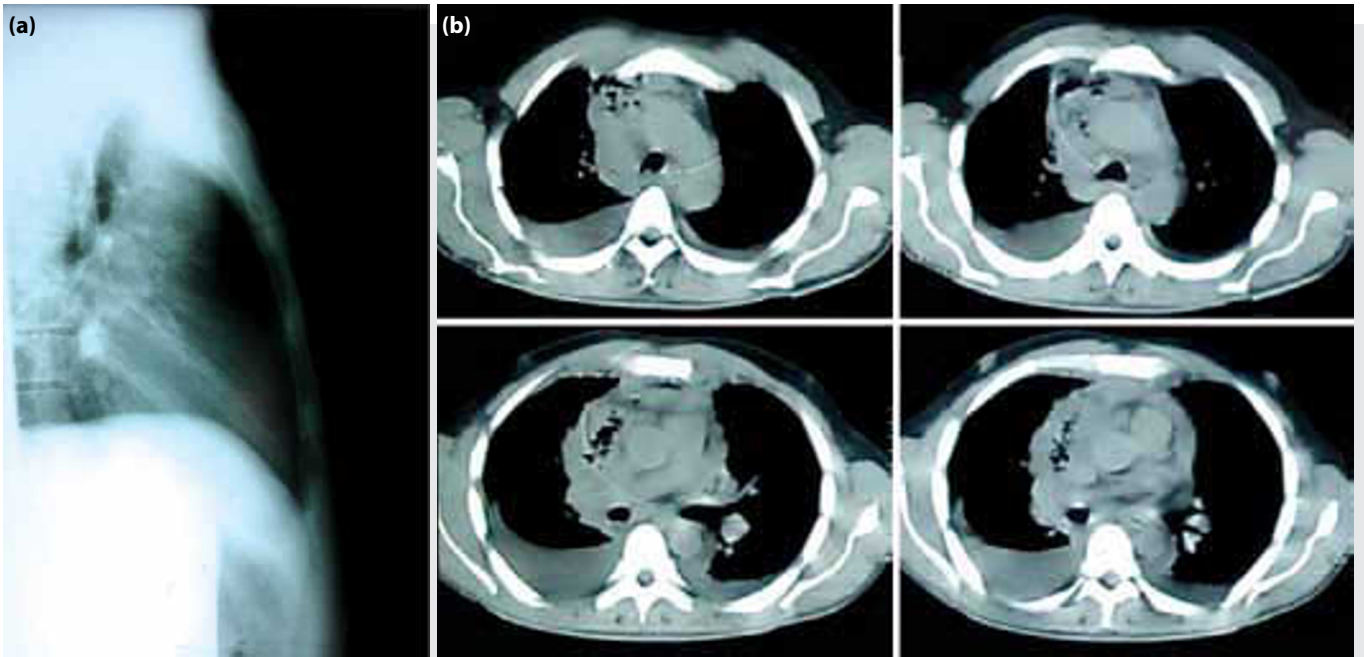
**Submitted:** May 17, 2013 **Accepted:** July 25, 2013 **Published online:** September 24, 2013

**Correspondence:** Dr. Pouya Paknejad. Emergency Department, Imam Reza Hospital, Tabriz, Iran.

**e-mail:** pooya.paknejad@gmail.com

Open access under [CC BY-NC-ND license](#).





**Figure 1.** (a) Normal chest X-Ray. (b) Thoracic computerized tomography images. Air and fluid collection in the mediastinum, bilateral pleural effusion and pericardial effusion as seen.

severe sternal pain and swelling on xiphoid. He was toxic and had high fever (39.1 °C) and tachycardia (135 beats per minute). Initial laboratory findings of significance showed 27,000/mm<sup>3</sup> leukocytes, 12.5 mg/dl hemoglobin, and 127 mEq/lit Na. CXR was performed and showed mediastinal widening and an osteomyelitis on sternum. A thoracic computerized tomography (CT) revealed air and fluid collection in mediastinum, bilateral pleural effusion, and pericardial effusion (Figure 1b). A chest tube was placed on the right side, which had more effusion, and purulent fluid was drained. The patient's symptoms improved partially after drainage of effusion. Esophagus was normal in barium swallow.

Patient admitted to thoracic surgery ward and underwent an anterolateral thoracotomy and debridement of necrotic tissues of mediastinum. A pericardial window was performed and intravenous administration of antibiotics was started. Daily flushing of mediastinum continued until the discharge day. A week after discharge, the patient was again admitted in thoracic surgery ward due to the continuation of his symptoms. Daily pleural flushing and drainage of pleural fluid continued until a negative pleural effusion culture.

Ten days later, in his last follow up, the patient was pain free, not febrile, and ambulatory. Drains were removed. Right side chest tube had a small amount of bloody fluid. Laboratory results showed 5900 (cell/mm<sup>3</sup>) leukocytes and 10.1 (mg/dl) hemoglobin.

## Discussion

Acute mediastinitis is a surgical emergency that has a high rate of mortality, ranging from 14% to 42%.<sup>[1]</sup> In most cases acute infection of mediastinum occurs because of esophageal rupture caused by neoplasm, trauma, or medical examination or treatment.<sup>[4]</sup> Macrí et al. studied 26 cases of mediastinitis and showed that in 64% of patients, infection originated from esophagus, and in 23% of cases it originated from oropharyngeal infection or dental or peritonsillar abscess named as descending necrotizing mediastinitis (DNM).<sup>[1]</sup> Estrera et al. published diagnostic criteria for DNM in 1983.<sup>[5]</sup> Symptoms and signs of mediastinitis such as fever, chest pain, leukocytosis, and high erythrocyte sedimentation rate are not specific but can give a clue for diagnosis in patients with a risk factor for mediastinitis.<sup>[6]</sup> Because of low sensitivity and specificity, conventional X-ray is not diagnostic for mediastinitis and may delay diagnosis and treatment, increasing mortality.<sup>[1,6]</sup> In any patient with high susceptibility of mediastinitis, computerized tomography should be performed.<sup>[1,6]</sup> Aggressive treatment should be started as soon as possible. Standard treatment for mediastinitis is surgical debridement of necrotic mediastinal tissue and adequate drainage of pleura and pericardium, followed by an appropriate antibiotic therapy and supportive medical care in an intensive care unit.<sup>[1,6]</sup> Although esophageal rupture is the main cause of mediastinitis, in our case the esophagus was normal and intact in both barium swallow and MRI. There was no evidence of oropharyngeal and dental infection and Estrera criteria for DNM were not fulfilled. There was a delay

in diagnosis because of mismanagement of patient's chest pain, showing the low sensitivity of plain chest radiography for mediastinitis. Despite the delayed treatment, the patient survived the condition, which shows the importance of aggressive treatment with adequate debridement and early antibiotic therapy. Patient's healthy condition before mediastinitis and no existence of comorbidities were positive factors in his survival.

### Conflict of Interest

The authors declare that there is no potential conflicts of interest.

### References

1. Macrí P, Jiménez MF, Novoa N, Varela G. A descriptive analysis of a series of patients diagnosed with acute mediastinitis. [Article in Spanish] *Arch Bronconeumol* 2003;39:428-30. [Abstract] [CrossRef](#)
2. De Feo M, Gregorio R, Della Corte A, Marra C, Amarelli C, Renzulli A, et al. Deep sternal wound infection: the role of early debridement surgery. *Eur J Cardiothorac Surg* 2001;19:811-6. [CrossRef](#)
3. Dwivedi MK, Pal RK, Gupta R, Rizvi SJ, Singh RP, Borkar PB. CT finding of descending necrotizing mediastinitis. *Ind J Radiol Imag* 2001;11:131-4.
4. Kurowski K, Matuszek I, Nunez CF. Successful outcome of descending necrotizing mediastinitis due to neck trauma. *Pol J Radiol* 2011;76:65-7.
5. Estrera AS, Landay MJ, Grisham JM, Sinn DP, Platt MR. Descending necrotizing mediastinitis. *Surg Gynecol Obstet* 1983;157:545-52.
6. Kilic D, Findikcioglu A, Ates U, Hekimoglu K, Hatipoglu A. Management of descending mediastinal infections with an unusual cause: a report of 3 cases. *Ann Thorac Cardiovasc Surg* 2010;16:198-202.