



Access this article online

Quick Response Code:



Website:  
www.turkjemergmed.org

DOI:  
10.4103/2452-2473.276383

# Barium sulfate aspiration: Is early bronchioalveolar lavage a life-saving procedure?

Amarjeet Kumar<sup>1</sup>, Ajeet Kumar<sup>2\*</sup>, Neeraj Kumar<sup>1</sup>, Chandni Sinha<sup>2</sup>, Jitendra Kumar Singh<sup>2</sup>

Departments of <sup>1</sup>Trauma and Emergency and <sup>2</sup>Anaesthesia, All India Institute of Medical Sciences, Patna, Bihar, India

Received: 01-10-2019  
Accepted: 07-11-2019  
Published: 28-01-2020

ORCID:  
0002-4272-5750  
0002-1464-6684  
0002-9161-7000  
0002-4107-2671  
0003-4115-4578

Address for  
correspondence:  
Dr. Ajeet Kumar,  
112, Block 2, Type 4,  
AIIMS Residential  
Complex, Khagaul,  
Patna, Bihar, India.  
E-mail: ajeetanaes@  
gmail.com

## Abstract:

Aspiration of barium sulfate is a well-known complication, occurring accidentally during contrast-enhanced examinations of the upper gastrointestinal system. Massive aspiration of contrast material causes mechanical obstruction that increases alveolar dead space leading to altered ventilation/perfusion (V/Q) ratio with secondary respiratory failure and death. The potential treatment strategies include early recognition of predisposing factors, pretreatment with antireflux medications, such as domperidone, correct choice of contrast media, and use of retroesophageal suction catheter during barium swallow study. We report a case of barium swallow aspiration, which was successfully managed by early institution of bronchioalveolar lavage (BAL) and positive pressure mechanical ventilation. Till date, BAL has not been recommended for the same, with studies showing it can worsen the clinical scenario.

## Keywords:

Aspiration pneumonia, barium, barium sulfate, bronchioalveolar lavage

## Introduction

Aspiration of barium sulfate is a known complication occurring accidentally during contrast-enhanced examination of the upper gastrointestinal system.<sup>[1]</sup> The chances of barium sulfate aspiration are increased in certain conditions such as extremes of age, low level of consciousness, anatomical and functional integrity of the oropharyngeal and esophageal segments, disordered swallowing, neuromuscular dysfunction, broncho-oesophageal fistula, alcoholism, head and neck cancer, and psychological illness that is commonly associated with functional gastrointestinal disorders.<sup>[2-5]</sup> The mortality rate after massive barium aspiration is approximately 30% and

can exceed 50% in patients who present with initial shock or apnea, secondary aspiration pneumonia, or adult respiratory distress syndrome.<sup>[6]</sup>

## Case Report

We present a case of a 60-year-old male with a history of dysphagia. During barium swallow study, the patient aspirated a large amount of barium following which he became dyspneic and had labored breathing. His examination showed a respiratory rate >35 breaths/min, tachycardia (heart rate >120 beat/min), blood pressure 160/100 mmHg, and SPO<sub>2</sub> <90% despite oxygen flow 15lit/min by mask. Arterial blood gas shows hypoxemia (PO<sub>2</sub> 86.7 mmHg on oxygen flow 15 lit/min). Lung auscultation detected crepitation in both lung bases. On chest X-ray, we found

This is an open access journal, and articles are distributed under the terms of the Creative Commons Attribution-NonCommercial-ShareAlike 4.0 License, which allows others to remix, tweak, and build upon the work non-commercially, as long as appropriate credit is given and the new creations are licensed under the identical terms.

**How to cite this article:** Kumar A, Kumar A, Kumar N, Sinha C, Singh JK. Barium sulfate aspiration: Is early bronchioalveolar lavage a life-saving procedure? Turk J Emerg Med 2020;20:50-3.

For reprints contact: reprints@medknow.com

barium sulfate aspiration involving the right and left main stem bronchi, bronchus intermedius, lower lobe basal, and segmental bronchi resembling a tree-in-bud appearance [Figure 1]. The patient was immediately shifted to intensive care unit (ICU) for intubation, and positive pressure mechanical ventilation was ensued. The patient underwent early bronchoalveolar lavage (BAL), and large amount of barium particles was suctioned into suction jar [Figure 2]. Postural drainage techniques were also performed. After 4 h, patients developed shock which was managed successfully by fluid resuscitation and inotropic support (infusion noradrenaline). Injection hydrocortisone 100 mg thrice daily, broad-spectrum antibiotics with coverage of gut flora, and nebulization with N-acetylcystein were given. After 24 hours the patient was stable hemodynamically and was extubated. Post extubation, the patient had an oxygen saturation of 99% on 5 litres of oxygen. The patient was shifted to ward on the 3<sup>rd</sup> day. On the 6<sup>th</sup> day, the patient again aspirated oral feed and gastric contents in ward. He was shifted to ICU but succumbed to sepsis on the 14<sup>th</sup> day.

### Discussion

Barium sulfate is a relatively insoluble salt of barium used as a radiographic contrast medium in the examination of the oropharynx and esophagus. Massive aspiration contrast material causes mechanical obstruction that increases alveolar dead space leading to altered ventilation/perfusion (V/Q) ratio with secondary respiratory failure, which can put the patient's life at risk.<sup>[7]</sup> Various segments of the lung gets involved according to the patients position during aspiration: 1. basal segments of lower lobes: erect posture 2. middle lobe: forward bending 3. posterior segment of lower lobe: recumbent position.<sup>[2,4]</sup> The main symptom in these patients is cough. Respiratory infection symptoms can appear later on if there has been simultaneous gastric content aspiration.

There are two types of barium particles present inside the lung after aspiration: one that adheres to epithelial

lining and other which is found freely inside the lumen of bronchial tree. The barium particle that adheres to the epithelial surface is not eliminated by BAL or coughing. It accumulates in alveolar spaces or peribronchial interstitial tissue and is phagocytized by alveolar macrophages leading to fibrosis.<sup>[3]</sup> In our patient, BAL might have worked by washing the barium particles present freely inside the lumen of the bronchial tree, decreasing the barium load inside the lungs [Figure 2]. Radiological improvement may not be seen as barium particles adhere to epithelial surface giving the opacified appearance.

Previously, Tamm and Kortsik did not recommend BAL because of the danger of dissemination of the contrast medium into the bronchioalveolar system.<sup>[2]</sup> We did not notice such a phenomenon following lavage in our patient as seen in the X-ray. The treatment is based on common sense and clinical judgment as no prospective controlled trials on the treatment are available.

Plain chest radiographs remain the modality of diagnosis if aspiration is suspected.<sup>[4]</sup> Lung high-resolution computed tomography (HRCT) is indicated only in severe cases and is useful in evaluating long-term prognosis. We did not get HRCT in our patient as he was hemodynamically unstable and X-ray had already confirmed the diagnosis. Findings on X-ray or in lung CT may vary with time, due to a slow-progressive clearance

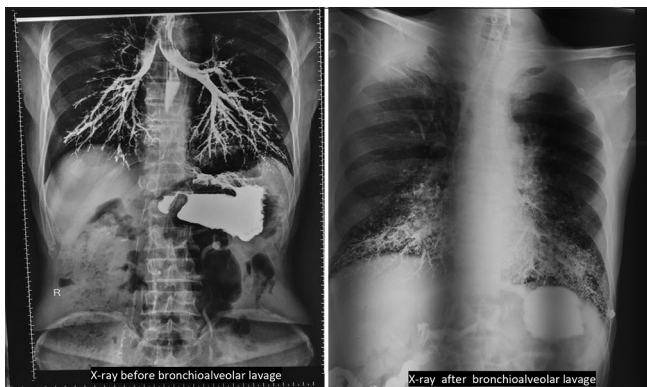


Figure 1: X-ray before/after bronchoalveolar lavage




Figure 2: Image of the suction device with aspirated barium

of the barium particles.<sup>[3]</sup> Postural techniques (e.g., lying on the side, rotating the head, and moving the head downward so the chin touches the neck) may minimize the risk of aspiration during oral administration of barium sulfate.<sup>[8]</sup> Postural drainage was also useful in our patient. Momosaki *et al.*<sup>[9]</sup> studied the effect of early rehabilitation by physical therapists in elderly patients with severe aspiration pneumonia; they found a reduction in 30-day in-hospital mortality rates.

In cases of a probable infection, antibiotic treatment with anaerobic coverage should be initiated.<sup>[2]</sup> Patients who have aspirated gastric material may present with dramatic signs and symptoms, such as gastric material in the oropharynx as well as wheezing, coughing, dyspnea, cyanosis, pulmonary edema, and hypoxia. Any of these signs or symptoms could rapidly progress to acute respiratory distress syndrome (ARDS).<sup>[10]</sup> Until now, no study has comprehensively described the clinical characteristics and outcomes of aspiration-related ARDS. As dysregulated inflammation is the cardinal feature of ARDS, systemic corticosteroids are often added to the treatment based on the discretion of the treating pulmonologist. However, the effect of systemic corticosteroids on the prognosis of the disease has not yet been revealed. Zhao *et al.*<sup>[11]</sup> in a retrospective study concluded that low-dose, short-term corticosteroid therapy may be expected to be effective in reducing hospital mortality in cases of aspiration-related ARDS, without notable side effects. The potential treatment strategies include early recognition of predisposing factors, pretreatment with antireflux medications, such as domperidone, correct choice of contrast media, and use of retroesophageal suction catheter during barium swallow study in high-risk cases to minimize the risk of massive barium aspiration and the ensuing complications.<sup>[12]</sup> Iodixanol (visipaque) is a new iso osmolar contrast medium, formulated with sodium and calcium in a ratio equivalent to blood. Mainly used as an intraarterial or intravenous agent, it has very less aspiration hazard.<sup>[13]</sup> Endoscopic evaluation of dysphagia may provide a safer alternative to barium studies in patients at risk of aspiration.<sup>[14]</sup> The prognosis of the patient following barium aspiration depends on multiple factors [Table 1]. Institution of early tracheostomy can be helpful in postural drainage and preventing further aspiration. In our case, we tracheostomized the patient following aspiration the second time but were not successful in saving the patient.

## Conclusion

Early institution of BAL and positive pressure mechanical ventilation becomes lifesaving after massive barium sulfate aspiration despite no radiological improvement. Clinical improvement cannot be correlated with

**Table 1: Factor affecting prognosis after barium sulfate aspiration**

### Factors causing poor prognosis after barium aspiration

|   |
|---|
| Volume of aspirated material                      |
| High concentration of barium solution             |
| Barium aspiration associated with gastric content |
| Extent of tracheobronchial distribution           |
| Physical condition of the patient                 |
| Delayed recognition and treatment                 |
| Patient's with comorbid disease                   |

radiological improvement as radiological improvement takes long time.

## Declaration of patient consent

The authors certify that they have obtained all appropriate patient consent forms. In the form the patient(s) has/have given his/her/their consent for his/her/their images and other clinical information to be reported in the journal. The patients understand that their names and initials will not be published and due efforts will be made to conceal their identity, but anonymity cannot be guaranteed.

## Acknowledgement

We would like to thank Dr Bhartendu bharti, Assistant Professor, Department of ENT, AIIMS, Patna for providing constant support in writing of the study.

## Author contribution statement

AK and JKS managed the patient. AK and JKS followed the patient. CS reviewed the literatures. CS and NK wrote the draft. All authors revised and approved the final version of the manuscript.

## Funding

None.

## Conflicts of interest

None.

## References

1. Katsanoulas C, Passakiotou M, Mouloudi E, Georgopoulou V, Gritsi-Gerogianni N. Severe barium sulphate aspiration: A report of two cases and review of the literature. *Signa Vitae* 2007;2:25-8.
2. Tamm J, Kortsik C. Severe barium sulfate aspiration into the lung: Clinical presentation, prognosis and therapy. *Respiration* 1999;66:81-4.
3. Venkatraman B, Rehman HA, Abdul-Wahab A. High resolution computed tomography appearances of late sequelae of barium aspiration in an asymptomatic young child. *Saudi Med J* 2005;26:665-7.
4. Voloudaki A, Ergazakis N, Gourtsoyiannis N. Late changes in barium sulfate aspiration: HRCT features. *Eur Radiol* 2003;13:2226-9.
5. Kaira K, Takise A, Goto T, Horie T, Mori M. Barium sulphate aspiration. *Lancet* 2004;364:2220.
6. Franquet T, Giménez A, Rosón N, Torrubia S, Sabaté JM, Pérez C. Aspiration diseases: Findings, pitfalls, and differential diagnosis. *Radiographics* 2000;20:673-85.
7. Fruchter O, Dragu R. Images in clinical medicine. A deadly examination. *N Engl J Med* 2003;348:1016.

8. Rasley A, Logemann JA, Kahrilas PJ, Rademaker AW, Pauloski BR, Dodds WJ. Prevention of barium aspiration during videofluoroscopic swallowing studies: Value of change in posture. *AJR Am J Roentgenol* 1993;160:1005-9.
9. Momosaki R, Yasunaga H, Matsui H, Horiguchi H, Fushimi K, Abo M. Effect of early rehabilitation by physical therapists on in-hospital mortality after aspiration pneumonia in the elderly. *Arch Phys Med Rehabil* 2015;96:205-9.
10. Marik PE. Aspiration pneumonitis and aspiration pneumonia. *N Engl J Med* 2001;344:665-71.
11. Zhao JN, Liu Y, Li HC. Corticosteroids in treatment of aspiration-related acute respiratory distress syndrome: Results of a retrospective cohort study. *BMC Pulm Med* 2016;16:29.
12. Belafsky PC, Mehdizadeh OB, Ledgerwood L, Kuhn M. Evaluation of hypopharyngeal suction to eliminate aspiration: The retro-esophageal suction (REScue) catheter. *Dysphagia* 2015;30:74-9.
13. Davenport D, Cohen MD, Hanna MP, Bugaieski E, Heifetz SA. Studies of iodixanol in the rabbit lung and peritoneum. *Pediatr Radiol* 1999;29:724-30.
14. Brady S, Donzelli J. The modified barium swallow and the functional endoscopic evaluation of swallowing. *Otolaryngol Clin North Am* 2013;46:1009-22.