



Case Report

A life-threatening condition: The pulmonary artery air embolism

Emin Uysal*, Nagihan Alkan, Betül Cam

Department of Emergency Medicine, University of Health Sciences, Bağcılar Training and Research Hospital, Istanbul, Turkey

ARTICLE INFO

Keywords:

Air embolism
Pulmonary artery
Injection of contrast agent

ABSTRACT

Introduction: Air embolism is a very rare condition which occurs when air or gas enter into the vascular system in either the venous or arterial route. It can occur following a variety of circumstances ranging from invasive procedures to either blunt or penetrating trauma conditions.

Case presentation: We present a case of a 39-year-old male who had an air embolism in the pulmonary artery as a consequence of the injection of a contrast agent. He had dyspnea and chest pain following a contrast-enhanced chest computed tomography imaging. He was successfully treated and discharged from our hospital.

Conclusion: Air embolism is rare, but can be fatal. The critical care providers should be familiar with the signs indicating air embolism and be ready to perform the main therapeutic maneuvers. Early detection of this clinical condition is essential to prevent morbidity and mortality.

1. Introduction

Pulmonary air embolism is an infrequent condition which can be seen following a penetrating or blunt trauma or some invasive procedures such as endoscopy, angiography, tissue biopsy, and peripheral venous access.^{1–3} Contrast agents are used in computed tomography (CT) scan to get a clearer imaging to help healthcare personnel to diagnose medical conditions. Automatic power injectors are used as an adjunct for fast contrast injections during CT procedure. However, these tools may also cause a particularly high-risk situation: accidental rapid injection of air into the venous circulation. Some examples are already reported in the literature: Abernathy et al.⁴ reported a fatal case with the massive air embolism following the use of an intravenous infusion pump. Therefore, awareness of the possible complications after some interventional procedures may help to prevent or at least reduce the risk of potentially unwanted outcomes.⁵ In this case report, we presented a 39-year-old male patient's contrast-enhanced chest computed tomography imaging which shows pulmonary artery air embolism causing acute dyspnea and chest pain due to injection of a contrast agent.

2. Case presentation

A 39-year-old male presented to our emergency department with pain in the left anterior hemithorax following a fall from a height of

2 m. No alcohol or drug use or no remarkable medical history was reported. He appeared in a good general status and had no dyspnea. His Glasgow Coma Scale (GCS) was 15, blood pressure (BP):176/80 mmHg, heart rate (HR):82 beats/min, respiratory rate (RR):20/min, SaO₂:95%, body temperature:36.3 °C. On physical examination, he reported pain with palpation to the left anterior hemithorax. Respiratory sounds heard on auscultation at bilateral sides were normal. No pathological findings were detected in other systemic examinations. Venous line was performed with a 20 G vascular line catheter into antecubital vein. Laboratory test yielded the following results; White blood cell (WBC):11700, Hemoglobin (Hg):13.2 g/dL, hematocrit (Hct):40.2%, Platelet (Plt):141000. Abdominal ultrasonography was performed on the patient, no pathology was detected. Because of trauma mechanism and physical examination he was sent to the contrast-enhanced abdomen and chest computed tomography with preliminary diagnoses of splenic injury and thoracic vascular injury. Contrast agent (iohexol 300 mg/100 ml) was administered with auto injector into antecubital vein. Following the contrast-enhanced computed tomography (CECT) acute dyspnea and chest pain developed in him. Abdominal tomography results also indicated no pathology, but two air bubbles were diagnosed in the main pulmonary artery on the chest CECT imaging (Figs. 1 and 2). Supplemental 100% oxygen via non-rebreather mask was initiated. The CT technician reported leakage of the contrast agent from one of the hubs on the venous cannula at the time of contrast injection which likely led to the introduction of air in the venous circulation. The

Peer review under responsibility of The Emergency Medicine Association of Turkey.

* Corresponding author. Department of Emergency Medicine, University of Health Sciences, Bağcılar Training and Research Hospital, Merkez Mahallesi, Dr. Sadik Ahmet Cd, 34100, Bağcılar, Istanbul, Turkey.

E-mail address: dreminuysal@hotmail.com (E. Uysal).

<https://doi.org/10.1016/j.tjem.2019.09.001>

Received 19 June 2019; Received in revised form 13 August 2019; Accepted 8 September 2019

Available online 17 September 2019

2452-2473/ 2019 Emergency Medicine Association of Turkey. Production and hosting by Elsevier B. V. on behalf of the Owner. This is an open access article under the CC BY-NC-ND license (<http://creativecommons.org/licenses/by-nc-nd/4.0/>).

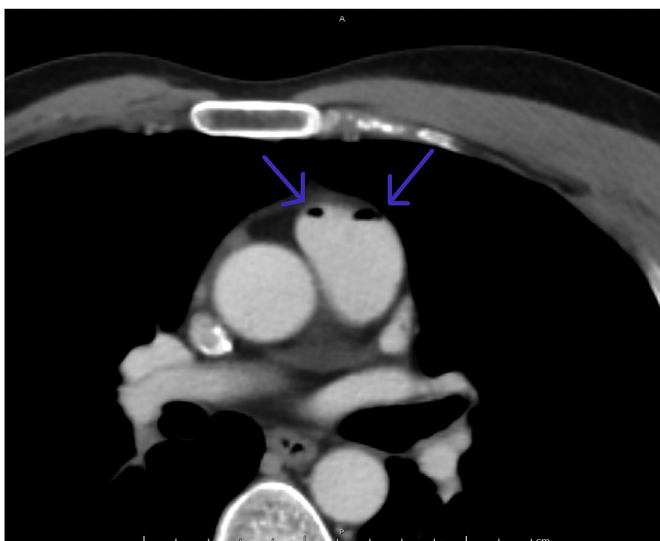

Fig. 1. Axial contrast-enhanced chest computed tomography image showing in the main pulmonary artery air bubbles (arrows).

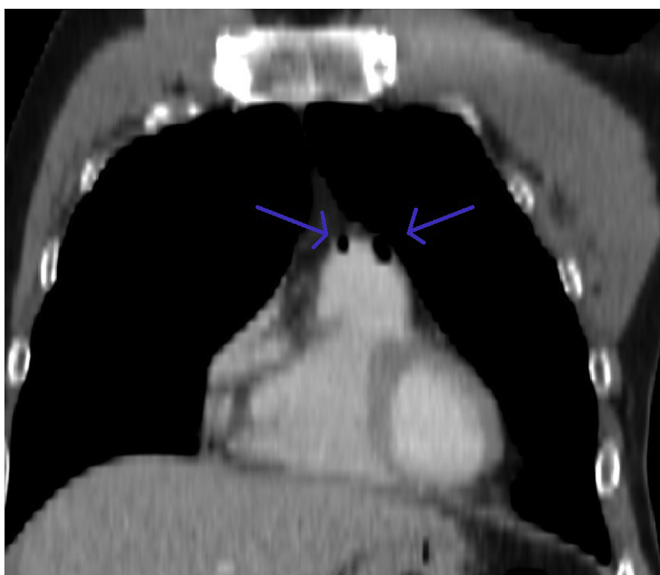


Fig. 2. Coronal contrast-enhanced chest computed tomography image showing in the main pulmonary artery air bubbles (arrows).

hemodynamic stability of the patient was maintained with Trendelenburg and left lateral decubitus positioning (Durant's maneuver). The patient was immediately transferred to the intensive care unit for close monitoring of his vital signs. His arterial blood gases on room air showed normal values. His electrocardiogram was sinus tachycardia. Laboratory tests yielded; a Troponin T value of 0.010 ng/mL (N:0–0.014), CK-MB value 67 U/L (N:20–170), and results of other laboratory tests were normal. A control chest CECT imaging was taken 6 hours later which showed no evidence of air embolism. This imaging and clinical relief were accepted as a sign of the complete resolution of the air embolism. He was followed up the next day symptom-free and discharged home.

3. Discussion

Pulmonary air embolism is a rare and potentially fatal complication of a variety of interventional procedures and can be result of certain clinical conditions.^{1–3} The mechanism of entry of gas into the vascular

system mostly occurs via intravenous route which moves through the right atrium and ventricle to the pulmonary circulation.⁶ Minor air bubbles can be eliminated by molecular diffusion of gas across the arterial wall into the alveolar spaces regardless of lung regional blood flow without any clinical manifestations.⁷ The severity of clinical symptom depends on either the location or amount of the air bubble.⁶ Also, body position may worsen the symptoms.⁸ Dyspnea, tachypnea, wheezing, chest pain, high central venous distension, hypotension, respiratory failure, and shock-like appearance could occur when large amounts of air enter into the pulmonary circulation in the air embolism.⁹ Any of sudden cardiovascular, respiratory and/or neurological problems after high-risk invasive procedures should prompt the suspicion of pulmonary air embolism.¹⁰ Other than the suspicion with some sudden clinical symptoms, there are no specific laboratory tests, physical findings for the pulmonary artery embolism.⁸ In these patients, immediate imaging tests should be performed to diagnose air embolism and other possible etiologies.^{1,10} On thorax CT, presence of air in the main pulmonary artery is a pathognomonic finding. Supportive treatment should be initiated promptly with 100% oxygen regardless of the type of embolism.⁵ Durant's maneuver, left-lateral decubitus and head-down positioning of the body to decrease air entry into the right ventricle outflow tract may be useful. Following treatments may also be applied: volume resuscitation, vasopressors or inotropes to enhance reabsorption, hyperbaric therapy to ensure dissolution of gases like nitrogen.^{3,10}

In our case, respiratory distress occurred rapidly after the injection of the contrast agent. Hyperbaric oxygen therapy deemed not indicated since the patient did not develop focal neurological deficit, and the symptoms were alleviated with supportive therapy. In particular, training of radiology technicians who use power injectors is essential to manage this avoidable hazard. In addition, early identification of this problem by the medical personnel who operate power injectors can lead to better outcomes.

4. Conclusion

Although the pulmonary air embolism is a very rare complication, its life-threatening potential makes prevention and prompt detection of this condition important. The critical care providers should especially be careful in cases where patients have sudden onset respiratory distress and/or chest pain.

Funding

No funding to declare.

Author contribution statement

NA and BC: analyzed and interpreted the data; EU: wrote the paper.

Conflict of interest statement

The authors declare no conflict of interest.

References

- Muth CM, Shank ES. Gas embolism. *N Engl J Med*. 2000;342:476–482.
- Lang D, Reinekt V, Horner A, et al. Complications of CT-guided transthoracic lung biopsy. A short report on current literature and a case of systemic air embolism. *Wien Klin Wochenschr*. 2018;130:288–292.
- Lanfranco J, Romero Legro I, Freire AX, et al. Pulmonary air embolism: an infrequent complication in the radiology suite. *Am J Case Rep*. 2017;18:80–84.
- Abernathy CM, Dickinson TC. Massive air emboli from intravenous infusion pump: etiology and prevention. *Am J Surg*. 1979;137:274–275.
- Mirski MA, Lele AV, Fitzsimmons L, et al. Diagnosis and treatment of vascular air embolism. *Anesthesiology*. 2007;106:164–177.
- Gordy S, Rowell S. Vascular air embolism. *Int J Crit Illn Inj Sci*. 2013;3:73–76.
- Presson Jr RG, Kirk KR, Haselby KA, et al. Fate of air emboli in the pulmonary

- circulation. *J Appl Physiol.* 1989;67:1898–1902.
8. Alvaran SB, Toung JK, Graff TE, et al. Venous air embolism: comparative merits of external cardiac massage, intracardiac aspiration, and left lateral decubitus position. *Anesth Analg.* 1978;57:166–170.
 9. Rahman ZU, Murtaza G, Pourmorteza M, et al. Cardiac arrest as a consequence of air embolism: a case report and literature review. *Case Rep Med.* 2016;3:1–4.
 10. McCarthy CJ, Behraves S, Naidu SG, et al. Air embolism: practical tips for prevention and treatment. *J Clin Med.* 2016;5(11):93.