



Case Report

Extensive pyomyositis of prevertebral muscles after acupuncture: Case report



M. Tucciarone*, S. Taliente, R. Gómez-Blasi Camacho, R. Souviron Encabo, R. González-Orús Álvarez-Morujó

Department of Otolaryngology, Hospital General Universitario Gregorio Marañón, Madrid, Spain

ARTICLE INFO

Keywords:

Acupuncture
Complication
Pyomyositis
Abscess

ORCIDiDs:

MT: 0000-0001-6463-1459
ST: 0000-0003-0041-381X
RGBC: 0000-0002-5392-6339
RSE: 0000-0003-4045-7323
RGOAM: 0000-0001-7327-6823

ABSTRACT

Introduction: Severe infectious diseases that require surgery after acupuncture therapy are quite rare. There are only a few cases of pyomyositis following acupuncture reported in the literature. This paper presents a case of cervical pyomyositis developed after such treatment.

Case presentation: A 36-year-old man presented with swelling and pain in the posterior cervical region as well as high fever and torticollis, after having received three sessions of acupuncture therapy during the preceding weeks aimed to treat his neck stiffness. Ultrasound guided fine needle aspiration (FNA) and contrast-enhanced Computed Tomography (CT) were performed, which showed a large abscess along the paraspinal muscles. The symptoms were resolved after surgical treatment and antibiotherapy.

Conclusion: Although highly infrequent, pyomyositis is a probable complication of acupuncture. In order to minimise the risk of complications, strict hygienic precautions and knowledge of the human anatomy are mandatory to decrease the rate of complications of acupuncture.

1. Introduction

Acupuncture is a form of traditional Chinese medicine extensively practiced all over the world to manage chronic pain and other conditions.¹ Although known as a safe procedure, various complications have been described including life-threatening ones. Generally, complications are minor, transient and mild, including bleeding, haematomas in the puncture site and pain associated with the procedure.² Current literature shows that suppurative complications can be catastrophic and may, in severe cases, lead to generalised sepsis and death.³ Attention must be paid to the sterilisation of the skin, strict hygiene precautions, and human anatomy to avoid possible complications related to this procedure. In this article, we report the case of a young male patient who developed an extensive cervical pyomyositis after acupuncture therapy, and required antibiotherapy and surgical drainage.

2. Case presentation

A 36-year-old man was admitted with pain, torticollis, swelling in the left posterior cervical region, asthenia and fever. His past medical records were unremarkable except for having undergone three sessions

of acupuncture during the last two weeks to treat mild neck stiffness. On admission, he was alert and communicative, and his body temperature was 39.1 °C. His physical exam revealed inflammation of his left posterior neck: the skin was hot, swollen and without tender or fluctuating areas. Neurological exam was normal. A complete blood count revealed a white blood cell count of $16700 \times 10^3/\mu\text{L}$ with 86.5% neutrophils. His C-reactive protein level was 19.3 mg/dL.

Ultrasonography of the neck revealed severe inflammation of the paraspinal muscles with images of fluid content (Fig. 1). A fine needle aspiration (FNA) was performed with an 18G needle, and the fluid content was sent for culture and antibiogram. Contrast-enhanced Computed Tomography (CT) demonstrated an extensive abscess ($7 \times 6.7 \times 4.2$ cm) localized in the paraspinal paravertebral space (Fig. 2).

Empirical intravenous antibiotic treatment with Amoxicillin/Clavulanic acid was initiated, and patient was taken to the operating room where the abscess was drained under general anesthesia via a posterior cervicotomy with a lateral paravertebral incision and discharge along the midline.

Group A Streptococcus pyogenes was cultured from both the FNA and surgical specimens. No events were observed during the

Peer review under responsibility of The Emergency Medicine Association of Turkey.

* Corresponding author. Avenida del Mediterraneo 43, 6a escalera derecha, 28007, Madrid, Madrid, Spain.

E-mail address: tucciaronemanuel@hotmail.it (M. Tucciarone).

<https://doi.org/10.1016/j.tjem.2019.03.003>

Received 17 February 2019; Received in revised form 19 March 2019; Accepted 21 March 2019

Available online 04 April 2019

2452-2473/ 2019 Emergency Medicine Association of Turkey. Production and hosting by Elsevier B. V. on behalf of the Owner. This is an open access article under the CC BY-NC-ND license (<http://creativecommons.org/licenses/by-nc-nd/4.0/>).

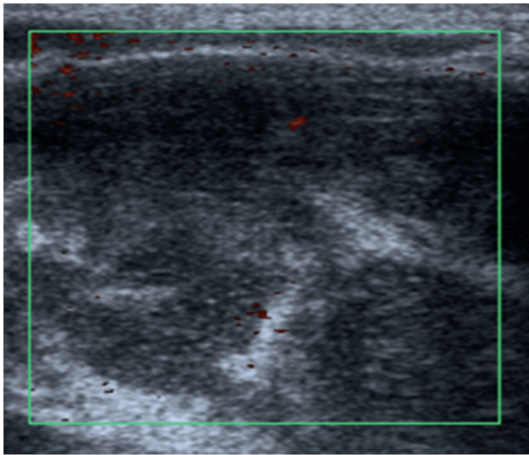


Fig. 1. Preoperative ultrasonography image revealing fluid content of the inflammatory reaction.

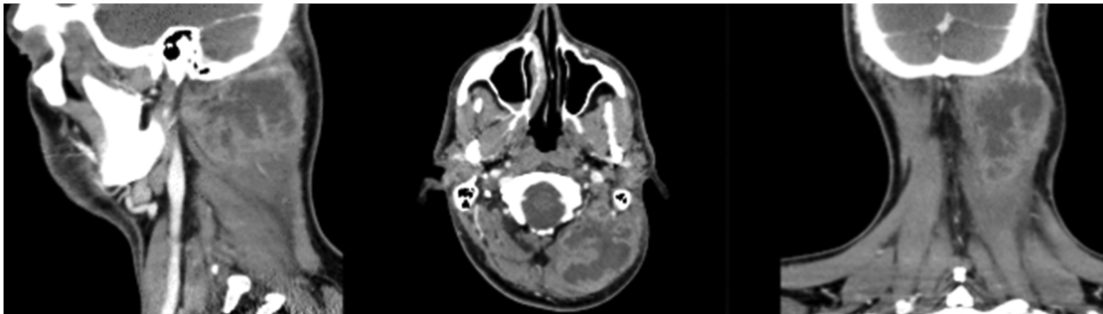


Fig. 2. Contrast-enhanced Computed Tomography scan of the neck showing the cervical fluid collection in sagittal, axial and coronal views.

postoperative period. Systemic Amoxicillin/Clavulanic acid treatment was continued for ten days. The patient was discharged to home on the postoperative tenth day.

3. Discussion

This study reports a rare case of an extensive pyomyositis of the prevertebral muscles following acupuncture, a standard procedure in traditional Chinese medical practice. Some reviews and studies suggest that acupuncture has clinical value to manage chronic pain, nausea, vomiting, headaches, and hypertension. Major complications are seen infrequently, however, have been reported in several case reports.⁴ White A., in a cumulative review, reported that the incidence of significant complications of acupuncture was of approximately 0.55 per 10.000 treatments.⁵ The most common significant events were soft tissue traumas and infections.⁴ Infection is the most frequent complication according to the literature. Even with the decrease in its incidence with the introduction of single-use needles, hepatitis B is still the most common disease transmitted using contaminated needles in acupuncture.^{4–6} Bacterial infections seem most likely occur by the injection of the patient's skin contaminants since achieving complete skin sterilisation is not possible.⁷ In general, traumatic lesions appear to be caused by practitioner's mistakes, including peripheral nerve injury, penetration to the lung, heart or spinal cord.⁵ Some authors described the rate of minor complications (pain, bleeding, localized infections)

related to the procedure that require intervention as 1.9%–7% of all complications.⁸ According to some authors, acupuncture may account for up to 15% of all spinal abscesses of iatrogenic origin.^{9,10}

Diabetes Mellitus, intravenous drug use and alcohol abuse are common risk factors for the development of abscesses, but in our patient, no direct risk factors were present.¹⁰ In our patient, the abscess was due to local bacterial infection of the muscle, probably caused by the injection of skin pathogens. Antibiotic treatment combined with surgical drainage is generally effective against pyomyositis with an excellent clinical outcome, usually without further complications.

4. Conclusion

Acupuncture is a relatively safe and common treatment practiced all over the world. Complications and their causes are well established in the scientific literature, compelling practitioners to give evidence-based information about potential complications including those that may be catastrophic and lead, in severe cases, to irreversible neurological deficits, sepsis and death. Strict hygienic precautions and knowledge of the

human anatomy are mandatory to decrease the rate of complications of acupuncture. Knowing these complications and avoiding them are the best way to ensure safe practice. Nonetheless, practitioners should be aware of their existence to identify and treat them rapidly.

References

1. Lao L, Hamilton GR, Berman BM, et al. Is acupuncture safe? A systematic review of case reports. *Altern Ther Health Med.* 2003 Jan-Feb;9(1):72–83.
2. Yamashita H, Tsukayama H, Hori N, et al. Incidence of significant adverse events associates with acupuncture. *J Altern Complement Med.* 2000;6:345–350.
3. Han Won-Seok, Yoon Young-Jin, Park Cheol-Whoo, et al. Staphylococcus aureus pericardial abscess presenting as severe sepsis and septic shock after acupuncture therapy. *Korean Circ J.* 2012;42:501–503.
4. White A. A cumulative review of the range and incidence of significant adverse events associates with acupuncture. *Acupunct Med.* 2004;19:112–116 2001.
5. Vincent C. The safety of acupuncture. *BMJ.* 2001;323(7311):467–468.
6. Yamashita H, Tsukayama H, White AR, et al. Systematic review of adverse events following acupuncture: the Japanese literature. *Complement Ther Med.* 2001;9(2):98–104.
7. Hoffman P. Skin disinfection and acupuncture. *Acupunct Med.* 2001;19(2):112–116.
8. Witt CM, Pach D, Reinhold T, et al. Treatment of the adverse effects from acupuncture and their economic impact: a prospective study in 73,406 patients with low back or neck pain. *Eur J Pain.* 2011 Feb;15(2):193–197.
9. Sendi P, Bregenzler T, Zimmerli W. Spinal epidural abscess in clinical practice. *GJM.* 2008;101:1–12.
10. Reihaus E, Waldbaur H, Seeling W. Spinal epidural abscess: a meta-analysis of 915 patients. *Neurosurg Rev.* 2000;232:175–204.