



Case Report

Can inhaled heroin be a cause of bilateral globus pallidus ischemic injury?

Iqra Iqbal^{a,*}, Muhammad Atique Alam Khan^b, Waqas Ullah^a^aAbington Memorial Hospital, Abington, PA, USA, ORCID: [0000-0002-7317-6803](https://orcid.org/0000-0002-7317-6803); WU: [0000-0002-4850-0309](https://orcid.org/0000-0002-4850-0309)^bKing Edward Medical University, Pakistan, MAAK: [0000-0002-5281-8889](https://orcid.org/0000-0002-5281-8889)

A B S T R A C T

Introduction: Bilateral globus pallidus lesions have been characteristically thought to be associated with global cerebral hypoperfusion and hypoxic changes. One of the important causative factors that need to be considered is the opiate drug abuse.

Case presentation: We present a case of a 50-year-old male who came to the hospital after being found down for 3 hours. He was found to have weakness of right upper and lower extremity. MRI showed bilateral globus pallidus infarcts. He later admitted to inhalation of heroin. Over the next few days, weakness started to improve and he was eventually discharged to rehabilitation. This case is a unique presentation of bilateral globus pallidus lesions after a one-time inhalation of heroin.

Conclusion: We, therefore, advocate that inhaled heroin should be considered as one of the causes of bilateral globus pallidus lesions, in addition to IV heroin and cocaine and physicians should be aware of the possibility of alternate forms of heroin abuse in such patients.

1. Introduction

Bilateral globus pallidus lesions (BGPL) have been characteristically associated with cerebral hypoperfusion and hypoxic changes mostly due to carbon monoxide, cyanide, and cocaine poisoning.¹ Globus pallidus has been selectively spared from ischemic injury but has rarely been reported with opioid poisoning.² Inhalation of heroin can be a cause of bilateral globus pallidus ischemic injury.^{3,4} We hereby present a case of a fifty-year-old male with right-sided motor weakness, who was found to have the bilateral ischemic injury of globus pallidus as a result of inhaling heroin. His weakness gradually improved after physical therapy.

2. Case presentation

A 50-year-old male was brought to the emergency department by his girlfriend due to an unwitnessed fall in the bathroom for about 2 h, and patient was transported to the hospital in the next hour. He inhaled an unknown amount of heroin and started developing symptoms after about 30 min of inhalation. Per patient, he was feeling short of breath and lightheaded prior to the fall. He had an episode of syncope but regained consciousness only after he was brought to the hospital. After regaining consciousness, he was complaining of right hip pain and weakness on the right side of his body. He denied any sensory deficit, speech difficulty, numbness, and tingling but he was unable to move his

right arm and leg. He denied any nausea, feeling of warmth, blurry vision, aura, tonic-clonic jerky movements, incontinence, recent infections or positional vertigo to suggest a possible cause of syncope. His only past medical history included asthma and left knee medial tear. There was no history of any psychiatric illness. Initially, he denied any use of alcohol intake, smoking or illicit drug use but on further detailed questioning, he told that he had inhaled heroin, although he did it for the first time in his life ever and had never injected and snorted any drugs before. He was a poor historian and was not able to quantify the amount of heroin that he inhaled. He denied any exposure to carbon monoxide, insect bite or any other toxin. He used to work at a meat processing plant and had no occupational chemical exposure.

On physical examination, he was vitally stable with a heart rate of 92 beats per minute (bpm), blood pressure (BP) 126/73, a temperature of 98.3 and respiratory rate of 16 per minute. On neurological examination, initially he was confused but he quickly regained full consciousness. His GCS was around 10 when EMS arrived at his home, but by the time we examined him in ER, he had GCS of 15. He had weakness in the right upper extremity with a power of 2/5 and right lower extremity with a power of 3/5. Sensory examination was normal and plantar reflexes were equivocal. Pupils were surprisingly normal in size and reactive bilaterally. Rest of the systemic examination was unremarkable.

Investigations showed slightly elevated white blood cell count, acidosis secondary to respiratory acidosis, acute kidney injury and

Peer review under responsibility of The Emergency Medicine Association of Turkey.

* Corresponding author.

E-mail addresses: driqraiqbal@gmail.com (I. Iqbal), dratiquealam@gmail.com (M.A. Alam Khan).

<https://doi.org/10.1016/j.tjem.2018.11.001>

Received 14 September 2018; Received in revised form 7 November 2018; Accepted 15 November 2018

Available online 22 November 2018

2452-2473/ 2019 Emergency Medicine Association of Turkey. Production and hosting by Elsevier B. V. on behalf of the Owner. This is an open access article under the CC BY-NC-ND license (<http://creativecommons.org/licenses/by-nc-nd/4.0/>).

Table 1
Laboratory investigation of the patient on presentation.

S.No	Investigation	Result	Normal range
1	Hemoglobin	13 g/dL	12–14 g/dL
2	White blood cells (WBCs)	14.7/L	4.5–11/L
3	pH	7.25	7.35–7.45
4	Blood urea nitrogen (BUN)	17 mg/dL	5–20 mg/dL
5	Lactate	1.2 mmol/L	0.5–1 mmol/L
6	Creatinine	2.32 mg/dL	0.7–1.2 mg/dL
7	Sodium	143 mEq/L	135–145 mEq/L
8	Potassium	4.2 mEq/L	3.5–5 mEq/L
9	Calcium	9 mg/dL	8.5–10.5 mg/dL
10	Phosphorus	4 mg/dL	2.5–4.5 mg/dL
7	pCO ₂	50	35–45 mmHg
8	AST	131 units/L	10–40 units/L
9	ALT	93 units/L	5–40 units/L
10	Albumin	4.7 g/L	3.5–5.5 g/L
11	TSH	0.478 mmol/L	0.4–4 mmol/L
12	Free T4	1.2 ng/dL	0.7–1.9 ng/dL
13	CK	5276	30–200 U/L
14	PO ₂	93.3 mmHg	80–100 mmHg
15	HCO ₃	22.5 mEq/L	22–28 mEq/L
16	Troponin T	< 0.1 ng/ml	< 0.4 ng/ml

elevated creatine kinase (CK) levels. ECG showed normal sinus rhythm and no arrhythmias were noted on telemetry during the hospital stay. The details are given below in Table 1.

Imaging results showed normal unenhanced computerized tomographic (CT) scan of the head. No evidence of any bleed or traumatic injury was found on CT scan. Duplex ultrasound of bilateral lower extremities was normal and did not show any clot. Echocardiography was also normal with normal right-sided heart and left ventricular ejection fraction of 55–60%. Electroencephalogram (EEG) was also done to rule out any seizures, but that also turned out to be normal. Magnetic resonance imaging (MRI) was eventually performed which revealed bilateral globus pallidus ischemic injuries (Figs. 1–3). Magnetic resonance angiography (MRA) of the head and neck vessels was normal and did not show any evidence of vascular narrowing.

He was initially treated with 325mg of aspirin. In the next few days, his weakness started to improve and the right leg weakness improved to 4/5, while the right upper extremity improved to 3/5. He did not undergo any symptoms of opioid withdrawal, which suggested that the use of heroin must have been once, short-term or sporadic. The patient was discharged to inpatient physical rehabilitation facility after five

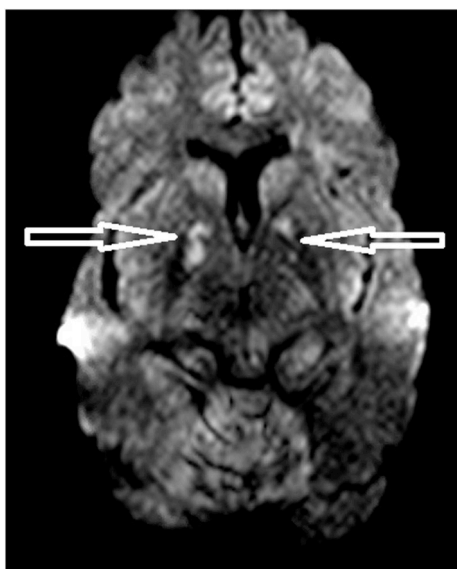


Fig. 1. MRI brain showing bilateral globus pallidus ischemic injuries.

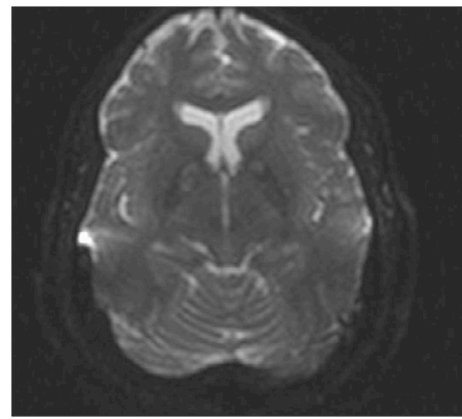


Fig. 2. Bilateral globus pallidus ischemic injury in diffusion-weighted images of MRI.

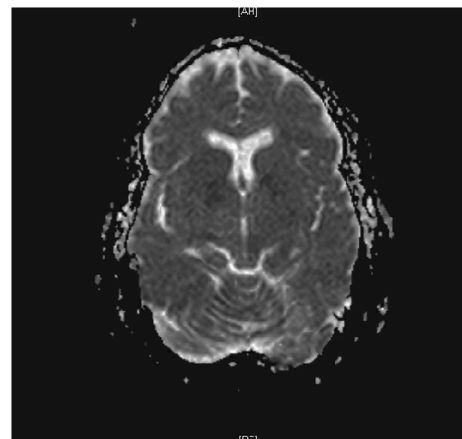


Fig. 3. ADC view showing decreased signals in the areas of bilateral globus pallidus infarcts.

days of hospitalization. He spent approximately ten days in rehabilitation, where his right leg weakness completely resolved and right upper extremity weakness improved significantly but still did not come back to baseline.

3. Discussion

Although there has been some data suggestive BGPL in about 5% of chronic iv heroin abusers, according to our literature search there has been only one other case report of a single dose of inhaled heroin-induced BGPL.^{1,4} Other neurological complications have been reported as hemiplegias, aphasias, hemiparesis, and hemianopia, cerebral arteritis and transverse myelitis.^{5–7}

Its presentation can fairly be like any stroke or Todd's palsy while the diagnosis is made by brain imaging. High-intensity BGPL seen on diffusion-weighted and T2 images are diagnostic in the settings of appropriate history.⁸ It is mostly seen with parenteral long-term heroin abuse possibly due to decreased neuronal population densities due to recurrent episodes of hypoxia secondary to suppression of respiratory center.^{9,10} Lesions in the deep white matter can also be seen, but only in cases of chronic cocaine abuse and rarely after acute intoxication. These findings are considered to be due to secondary demyelination due to intense vasoconstriction.^{11,12} No data has been suggestive of an inhaled single dose of heroine associated BGPL.

The recent shift in heroin use pattern, from injection to sniffing and smoking has contained the spread of HIV, hepatitis B, and C at the expense of potential fatal toxicities.¹³ Cone et al. has explained that the pharmacokinetics of IV and intranasal heroin are quite similar.

Similarly, there was no significant difference between the time to peak concentrations, mean elimination half-life, physiologic and behavioral effects and complications profile of the two routes.¹⁴ Our study endorse these findings and embark on the potentially life-threatening complication with a single dose of heroin that would otherwise be expected in chronic abusers. We conclude that inhaled opioids should no more be considered relatively safer and physicians should keep inhaled opioid-induced BGPL it in their list of differentials for stroke-like presentation.

Funding

No funding involved.

Conflict of interest statement

There are no financial and personal relationships with other people or organizations that could inappropriately influence (bias) our work.

CRediT authorship contribution statement

Iqra Iqbal: Writing – original draft. **Muhammad Atique Alam Khan:** Writing – review & editing. **Waqas Ullah:** Validation.

References

- Alquist CR, McGoey R, Bastian F, Newman W. Bilateral globus pallidus lesions. *J La State Med Soc.* 2012 May;164(3):145–146.
- Niehaus L, Rörich S, Meyer BU, Sander B. Nuclear magnetic resonance tomography detection of heroin-associated CNS lesions. *Aktuelle Radiol.* 1997 Nov;7(6):309–311.
- Büttner A, Mall G, Penning R, Weis S. The neuropathology of heroin abuse. *Forensic Sci Int.* 2000 Sep 11;113(1-3):435–442.
- Zuckerman GB, Ruiz DC, Keller IA, Brooks J. Neurologic complications following intranasal administration of heroin in an adolescent. *Ann Pharmacother.* 1996 Jul;30(7-8):778–781.
- Richter RW, Baden MM. Neurological complications of heroin addiction. *Trans Am Neurol Assoc.* 1969;94:330–332.
- Schein P, Yessayan L, Mayman C. Acute transverse myelitis associated with intravenous opium. *Neurology.* 1971;21:101–102.
- Brust J, Richter R. Stroke associated with addiction to heroin. *J Neurol.* 1976;39:194–199.
- Kadi R, Romy A, Stadnik T, Cannie M, Abiglia C, Davano L. Bilateral lesions of the globus pallidus in a young woman. *JBR-BTR.* 2014 Mar 1;97(2):118–120.
- Vila N, Chamorro A. Ballistic movements due to ischemic infarcts after intravenous heroin overdose: report of two cases. *Clin Neurol Neurosurg.* 1997 Dec 1;99(4):259–262.
- Andersen SN, Skullerud K. Hypoxic/ischaemic brain damage, especially pallidal lesions, in heroin addicts. *Forensic Sci Int.* 1999 May 31;102(1):51–59.
- Hantson P, Duprez T. Imagerie cérébrale et intoxications. *Reanimation.* 2009 Oct 1;18(7):598–605.
- De Roock S, Hantson P, Laterre PF, Duprez T. Extensive pallidal and white matter injury following a cocaine overdose. *Intensive Care Med.* 2007 Nov 1;33(11):2030–2031.
- Hosztafi S. Heroin addiction. *Acta Pharm Hung.* 2011;81(4):173–183.
- Cone EJ, Holicky BA, Grant TM, Darwin WD, Goldberger BA. Pharmacokinetics and pharmacodynamics of intranasal “snorted” heroin. *J Anal Toxicol.* 1993 Oct 1;17(6):327–337.