



Case Report

A diagnostic negative ultrasound finding in blunt abdominal trauma

Fikri M. Abu-Zidan^{a, b, *}, Husni S. Shalak^b, Mohammed A. Alhaddad^b^a Department of Surgery, College of Medicine and Health Sciences, UAE University, Al-Ain, United Arab Emirates^b Department of Surgery, Al-Ain Hospital, Al-Ain, United Arab Emirates

ARTICLE INFO

Article history:

Received 31 May 2018

Received in revised form

20 June 2018

Accepted 20 June 2018

Available online 25 June 2018

Keywords:

Injury

Rupture

Trauma

Ultrasound

Urinary bladder

ABSTRACT

Introduction: Ultrasound is an extension of the clinical examination and its findings should be correlated with the clinical picture as a whole to be useful. Hereby, we report a unique negative diagnostic ultrasound finding in blunt abdominal trauma which was not reported before.

Clinical presentation: A 50-year-old obese man presented complaining of severe generalized abdominal pain and inability to pass urine of three days duration after he slipped on his abdomen. The abdomen was distended and tender all over. There was no blood on the urethral meatus. FAST scan showed significant intra-peritoneal fluid. The urinary bladder could not be seen. A Foley catheter was inserted which drained 3 L of clear urine. The abdominal distention became less. Repeated FAST scan was completely negative. A clinical diagnosis of major intra-peritoneal rupture of the urinary bladder was made. Trauma CT scan and laparotomy confirmed the diagnosis.

Conclusions: The change of a positive FAST to a negative FAST was diagnostic of a major intra-peritoneal urinary bladder rupture even before performing a trauma CT scan. When performing FAST in blunt abdominal trauma, it is more useful to perform FAST before inserting a urinary catheter and it is advised to repeat it.

Copyright © 2018 The Emergency Medicine Association of Turkey. Production and hosting by Elsevier B.V. on behalf of the Owner. This is an open access article under the CC BY-NC-ND license (<http://creativecommons.org/licenses/by-nc-nd/4.0/>).

1. Introduction

Focused Assessment Sonography for Trauma (FAST) is commonly used as a bedside rapid diagnostic tool in multiple blunt trauma patients.¹ It is easy to learn and has high sensitivity in detecting free intra-peritoneal fluid.² Nevertheless, it cannot differentiate between different types of fluid which can be blood, bile, urine, or exudate.^{3,4} Ultrasound is an extension of the clinical examination. Its findings should be correlated with the clinical picture as a whole when answering specific urgent questions.⁵ Hereby, we report a unique negative diagnostic ultrasound finding in blunt abdominal trauma which was not reported before.

2. Case presentation

A 50-year-old obese man presented to the Emergency

Department of Al-Ain Hospital complaining of severe generalized abdominal pain, abdominal distension, and inability to pass urine of three days duration after he woke up from sleep to urinate at night and he slipped on his abdomen. The pain was initially mild and localized in the suprapubic region then it became more generalized, severe (8/10) and increased with movement.

On examination, his blood pressure was 145/85 mmHg, his pulse was 84 bpm and his temperature was 36.8 °C. The abdomen was distended and tender all over. There was no blood on the urethral meatus. Rectal examination was normal. FAST scan showed obvious significant intra-peritoneal fluid in the right and left upper quadrants of the abdomen and in the pelvis. The urinary bladder could not be seen. The initial FAST examination was done using a portable ultrasound machine (CX50, Philips) and a convex array abdominal probe by an experienced operator. The operator diagnosed 150 sonographic pathological cases as part of his surgical residency training program in Germany. A Foley catheter was inserted which drained 3 L of clear urine within 10 minutes. The abdominal distention became less. Repeated FAST scan 30 minutes after inserting the urinary catheter was completely negative (Fig. 1A–C). The repeated FAST examination was done using a portable ultrasound machine (MicroMaxx, Sonosite) and a small print convex array probe having a frequency of 3–5 MHz by an

* Corresponding author. Department of Surgery, College of Medicine and Health Sciences, UAE University, Al-Ain, United Arab Emirates.

E-mail addresses: fabuzidan@uaeu.ac.ae (F.M. Abu-Zidan), hshalak@dha.gov.ae (H.S. Shalak), dr_a_alhaddad@hotmail.com (M.A. Alhaddad).

Peer review under responsibility of The Emergency Medicine Association of Turkey.

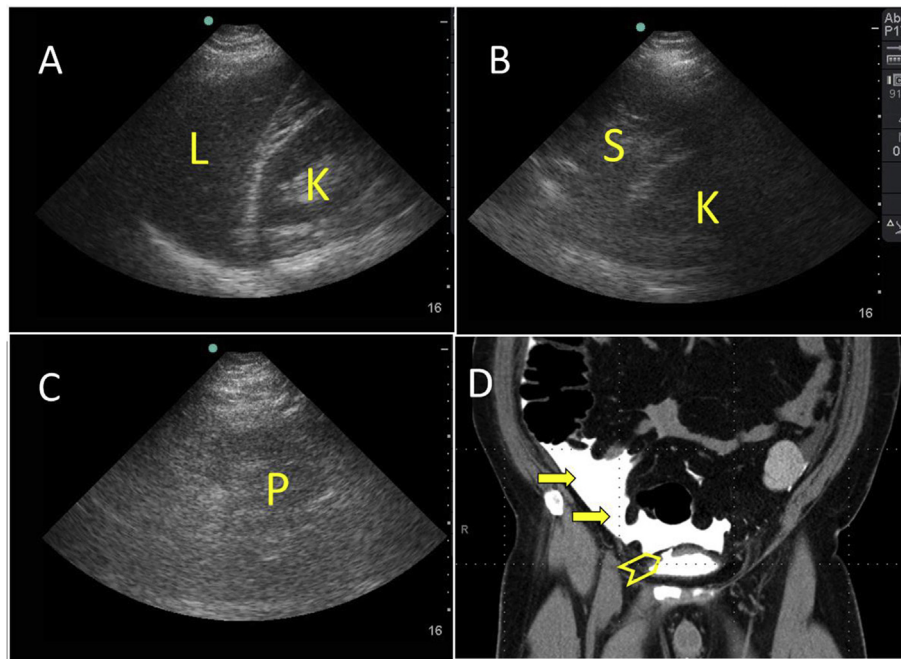


Fig. 1. Repeated FAST scan after insertion of a Foley catheter shows absence of intra-peritoneal fluid in the right upper quadrant (A) and left upper quadrant of the abdomen (B), and pelvis (C). The urinary bladder could not be visualized. CT scan (D) which was performed after contrast was instilled through the Foley catheter shows significant spillage of contrast (arrows) into the peritoneal cavity from the dome of the urinary bladder (arrow head). L = Liver, K = Kidney, S = Spleen, P = Pelvis.

operator having more than 27 years' experience in performing Point-of-Care Ultrasound (POCUS). A clinical diagnosis of major intra-peritoneal rupture of the urinary bladder was made. Contrast was instilled through the Foley catheter followed by CT scan of the abdomen. CT scan showed significant spillage of contrast from the urinary bladder into the peritoneal cavity which confirmed our diagnosis (Fig. 1D). Laparotomy confirmed the presence of a 10 cm intra-peritoneal rupture of the dome of the urinary bladder which was closed in 2 layers using Vicryl 3/0 (Fig. 2). There were no other

intra-abdominal injuries detected. The patient had smooth recovery and was discharged home on day 7.

3. Discussion

The binary answering approach (yes or no) of ultrasound for specific questions when managing trauma patients has simplified the decision making process. This approach, although needs experience, does not need extensive radiological details.^{6,7} Accordingly, POCUS became the clinical intra-abdominal inspection of a patient, and a critical decision tool, when done by an acute care physician.⁵

The association of presence of intra-peritoneal fluid and hypotension usually indicates intra-abdominal bleeding. Our patient was not hypotensive on presentation despite the presence of significant intra-peritoneal fluid. The injury occurred three days before presentation and the patient was hemodynamically stable. Despite that, intra-abdominal bleeding could not be completely ruled out. The change of FAST examination from a positive to a negative study combined with drainage of a large amount of clear urine through the Foley catheter was diagnostic of a major intra-peritoneal urinary bladder rupture. Abdominal ultrasound can detect as little as 10 ml of intra-abdominal fluid by experienced hands although up to 1 L may be needed to be detected by a non experienced operator.^{8,9} The second operator, who is highly experienced in performing POCUS, was surprised to find that FAST was completely negative. To reach proper diagnosis, he directly spoke with the first operator who confirmed that he was highly confident of his positive results. The patients' sitting position in the bed, the large unexplained amount of urine in the urinary bag, the experience of both operators, and thinking outside the box all helped in reaching the diagnosis of a major intra-peritoneal urinary bladder rupture that permitted complete drainage of the intra-peritoneal fluid through the urinary catheter. We are not aware of a similar case in the literature where indirect ultrasound findings were

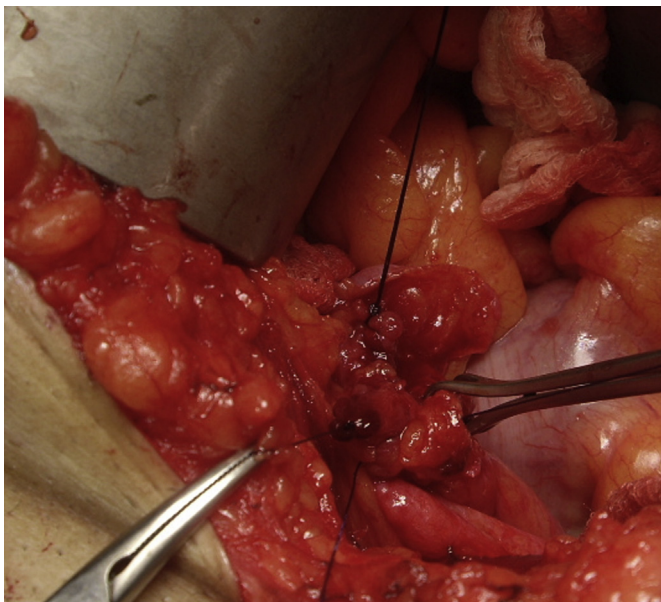

Fig. 2. Laparotomy confirmed the presence of a 10 cm intra-peritoneal rupture of the dome of the urinary bladder which was closed in 2 layers using Vicryl 3/0.

diagnostic. Urinary bladder wall rupture is difficult to directly visualize by ultrasound. Its sonographic findings consist of a contracted bladder with wall irregularities and presence of intraperitoneal fluid.¹⁰ The clinical diagnosis of our patient using FAST is very similar to the diagnosis of a rupture diaphragm when the instilled fluid of the diagnostic peritoneal lavage drains through a chest tube.

Finally, we have to acknowledge that this case report has a specific limitation. We regret that we could not capture the first positive FAST study in a video clip compared with the second one. The studies have been done by two different machines having different capabilities by two different operators at two different times. The first operator did not think that it was important to save the image because the patient had the injury 3 days before, was hemodynamically stable, and was planned to have an abdominal CT scan. The negative FAST has captured the attention of the second operator who documented it.

4. Conclusions

This case gives two important messages when performing FAST in blunt abdominal trauma. First, it is more useful to perform FAST before inserting a urinary catheter; and second, this case supports the value of repeating FAST in trauma patients. The change of a positive FAST to a negative FAST was diagnostic of a major intraperitoneal urinary bladder rupture even before performing a trauma CT scan.

Funding

None.

Contribution of authors

Fikri Abu-Zidan was the trauma surgeon in charge, performed

the second Point-of-Care Ultrasound (POCUS) study, diagnosed the case, had the idea, read the literature, wrote the first version of the paper, edited it, and approved the final version of the paper. Husni S. Shalak initially examined the patient, performed the first POCUS, participated in the idea and approved the final version of the paper. Mohammed A. AlHaddad operated on the patient and cared for him, participated in the idea and approved the final version of the paper.

Conflict-of-interest

All authors declare that they have no conflict of interest.

References

1. Abu-Zidan FM, Zayat I, Sheikh M, et al. Role of ultrasonography in blunt abdominal trauma: a prospective study. *Eur J Surg.* 1996;162:361–365.
2. Mohammad A, Hefny AF, Abu-Zidan FM. Focused assessment Sonography for trauma (FAST) training: a systematic review. *World J Surg.* 2014;38:1009–1018.
3. Radwan MM, Abu-Zidan FM. Focussed Assessment Sonograph Trauma (FAST) and CT scan in blunt abdominal trauma: surgeon's perspective. *Afr Health Sci.* 2006;6:187–190.
4. Jones AE, Mason PE, Tayal VS, et al. Sonographic intraperitoneal fluid in patients with pelvic fracture: two cases of traumatic intraperitoneal bladder rupture. *J Emerg Med.* 2003;25:373–377.
5. Abu-Zidan FM. Point-of-care ultrasound in critically ill patients: where do we stand? *J Emergencies, Trauma, Shock.* 2012;5:70–71.
6. Abu-Zidan FM, Freeman P, Mandivia D. The first Australian workshop on bedside ultrasound in the emergency department. *N Z Med J.* 1999;112:322–324.
7. Abu-Zidan FM, Dittrich K, Czechowski J, et al. Establishment of a "focused assessment Sonography for trauma" (FAST) course. *Saudi Med J.* 2005;26:806–811.
8. Branney SW, Wolfe RE, Moore EE, et al. Quantitative sensitivity of ultrasound in detecting free intraperitoneal fluid. *J Trauma.* 1995;39:375–380, 9.
9. Abu-Zidan FM, Siösteen AK, Wang J, et al. Establishment of a teaching animal model for sonographic diagnosis of trauma. *J Trauma.* 2004;56:99–104.
10. Wu TS, Pearson TC, Meiners S, et al. Bedside ultrasound diagnosis of a traumatic bladder rupture. *J Emerg Med.* 2011;41:520–523.