



Contents lists available at ScienceDirect

# Turkish Journal of Emergency Medicine

journal homepage: <http://www.elsevier.com/locate/TJEM>

## Case Report

# Gaboon viper envenomation: An unexpected injury by non-indigenous snake in South Korea

Young Gi Min, Seung Ho Ham, Yoon Seok Jung, Sangchun Choi\*

Department of Emergency Medicine, Ajou University School of Medicine, Suwon, South Korea

## ARTICLE INFO

### Article history:

Received 12 April 2018

Received in revised form

16 April 2018

Accepted 17 April 2018

Available online 27 April 2018

### Keywords:

Snake bites

Antivenins

Viperidae

Animals

Exotic

## ABSTRACT

In recent years, various kinds of non-indigenous snakes have become popular as domestic pets globally. If the snake is highly venomous, this would be a potentially life-threatening emergency for breeders. In such a case, the specific antidote should be administered immediately for saving the life. "Salmusa" genus (e.g. *Gloydius* genus) is a representative indigenous venomous snake in South Korea. Therefore, only one antidote for the "Salmusa" genus is commercially available in South Korea. The Gaboon viper (*Bitis gabonica*) inhabits in the rainforests of sub-Saharan Africa. Its venom is very toxic for mammals. Victims of a Gaboon viper bite could result in die unless the appropriate antidote is administered timely. We report a case of a 20-year-old male who completely recovered from a Gaboon viper envenomation after receiving "Salmusa" antivenom (Kovax®). This report reminds us that establishing an inventory of antidotes for potential toxic non-indigenous organisms is needed to enable successful treatment of emergency situations for public health.

Copyright © 2018 The Emergency Medicine Association of Turkey. Production and hosting by Elsevier B.V. on behalf of the Owner. This is an open access article under the CC BY-NC-ND license (<http://creativecommons.org/licenses/by-nc-nd/4.0/>).

## 1. Introduction

In recent years, various kinds of non-indigenous snakes have become popular as domestic pets globally.<sup>1</sup> If the pet is a venomous snake, this would be a potentially life-threatening medical emergency for breeders. Also, unavailability of antivenom can be catastrophic to a snake bite victim if the snake venom is highly toxic. The most effective treatment for a snake bite is the administration of the antidote.<sup>2</sup> Currently, only one kind of antidote for "Salmusa" genus (*Gloydius* genus) is commercially available in South Korea.<sup>2</sup>

The Gaboon viper (*Bitis gabonica*)'s venom is extremely toxic for mammals.<sup>3</sup> Someone bitten by a Gaboon viper bite could die unless the proper antidote is administered in timely manner.<sup>3</sup> We report a case of a 20-year-old male completely recovered from the Gaboon viper envenomation after being treated with administering a large dose of "Salmusa" antivenom.

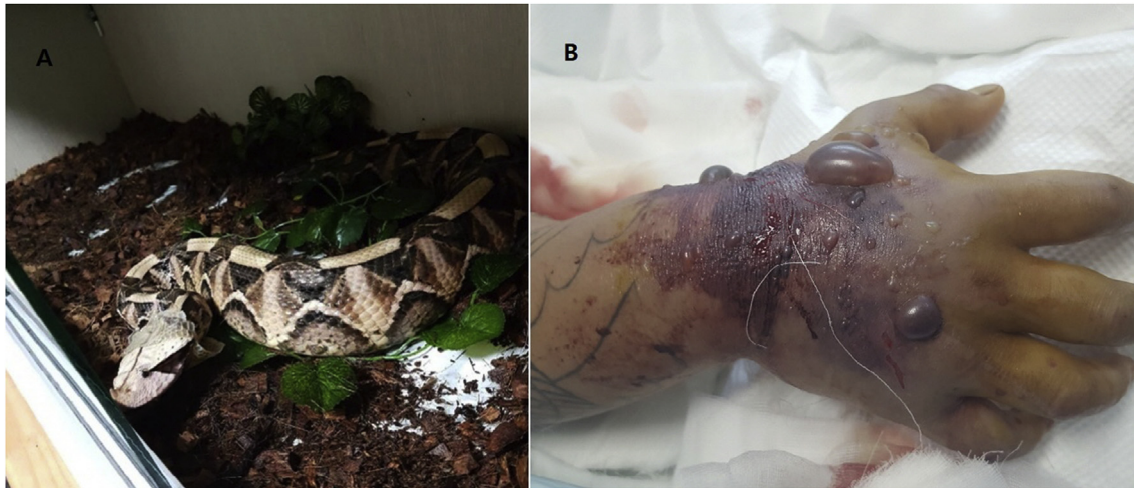## 2. Case

A 20-year-old man came to the emergency department complaining of pain and edema in his right arm after having been bitten on the right hand by his pet Gaboon viper, which was suspected of being smuggled from Africa (Fig. 1A). He had purchased the snake through an Internet club for snake owners and had raised it for about one year. The snake had attained a length of about 1.3 m. He had come to his local hospital 30 minutes after being bitten and had received 1 vial of antivenom (freeze-dried Salmusa antivenom; Kovax®) and 1 vial of tetanus toxoid. However, pain and edema continued and became worse. He was transferred to our emergency department 12 hours after being bitten. At the time of admission, fang marks were readily visible on the right hand, and the pain and edema extended to the right shoulder. Vital signs were blood pressure 109/71 mmHg, pulse rate 129 per minute (RPM), respiration rate 14 RPM, and body temperature 37 °C. The bitten hand had swelled so much that a fist could not be made (Fig. 1B). While the edema and pain were severe, no neurological symptoms were evident. Mild gross hematuria was present. Platelet count was 12,000/mm<sup>3</sup>, prothrombin time (PT) exceeded 150 sec, activated partial thrombin time (aPTT) exceeded 200 sec, and fibrinogen level was less than 35 mg/dl. Venom-induced consumption coagulopathy (VICC) was suspected to have occurred. He was admitted to the

\* Corresponding author. Department of Emergency Medicine, Ajou University School of Medicine, 164Worldcup-ro, Yeongtong-gu, Suwon, 16499, Republic of Korea.

E-mail address: [avenue59@ajou.ac.kr](mailto:avenue59@ajou.ac.kr) (S. Choi).

Peer review under responsibility of The Emergency Medicine Association of Turkey.



**Fig. 1. The culprit snake (A) and biting site (B).**

A. The Gaboon viper has typically a tiny pair of horns between the nostrils and the two stripes below the eye. B. Two large bullae around the anatomical snuff box are suspected of being the fang sites.

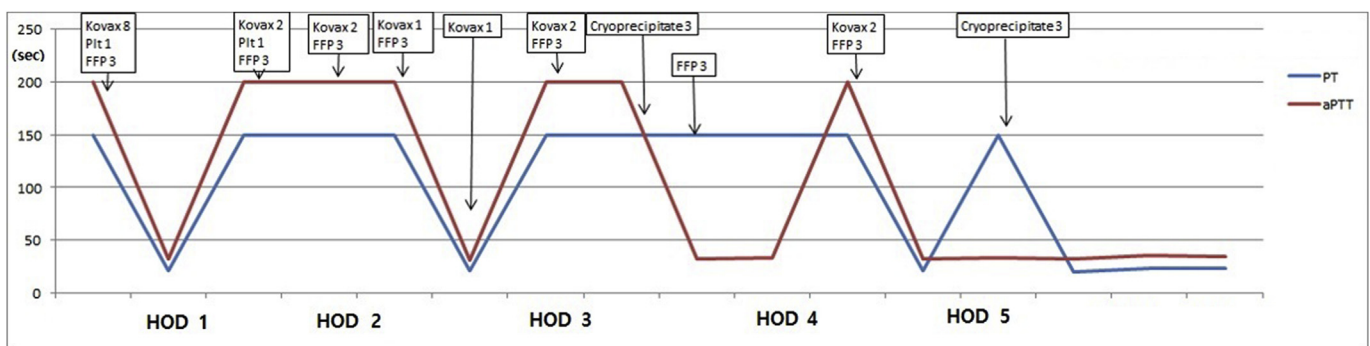
intensive care unit. PT and aPTT changed upon treatments including antivenom administrations and transfusions (Fig. 2). Wound management comprised of twice daily change of dressing and identification of compartment syndrome. VICC and the local wound had stabilized by day 6 of hospitalization. There was no evidence of serum sickness until hospital discharge on day 13 of hospitalization. Fig. 3 showed changes in local wound status according to the treatments.

### 3. Discussion

Looking at the growing popularity of raising non-indigenous pet, injuries associated with raising pet become increasingly frequent and will be potentially life-threatening.<sup>1</sup> Until the 1990s, North American antivenom (crotalidae polyvalent antivenom) was only used for treating victims with “Salmusa” bite in Korea.<sup>2</sup> Kovax<sup>®</sup>, which is currently available in Korea, is a monovalent antibody for *Gloydius blomhoffii* venom.<sup>2</sup> The “Salmusa” genus (e.g. *G. blomhoffii brevicandus*, *G. saxatilis*, and *G. ussuriensis*) is included in the family Viperidae.<sup>2</sup> There are three subfamilies: crotalinae, viperinae, and azemiopinae.<sup>4</sup> The “Salmusa” and the Gaboon viper belong to the same family. However, “Salmusa” belongs to the crotalinae subfamily, while the Gaboon viper belongs to the

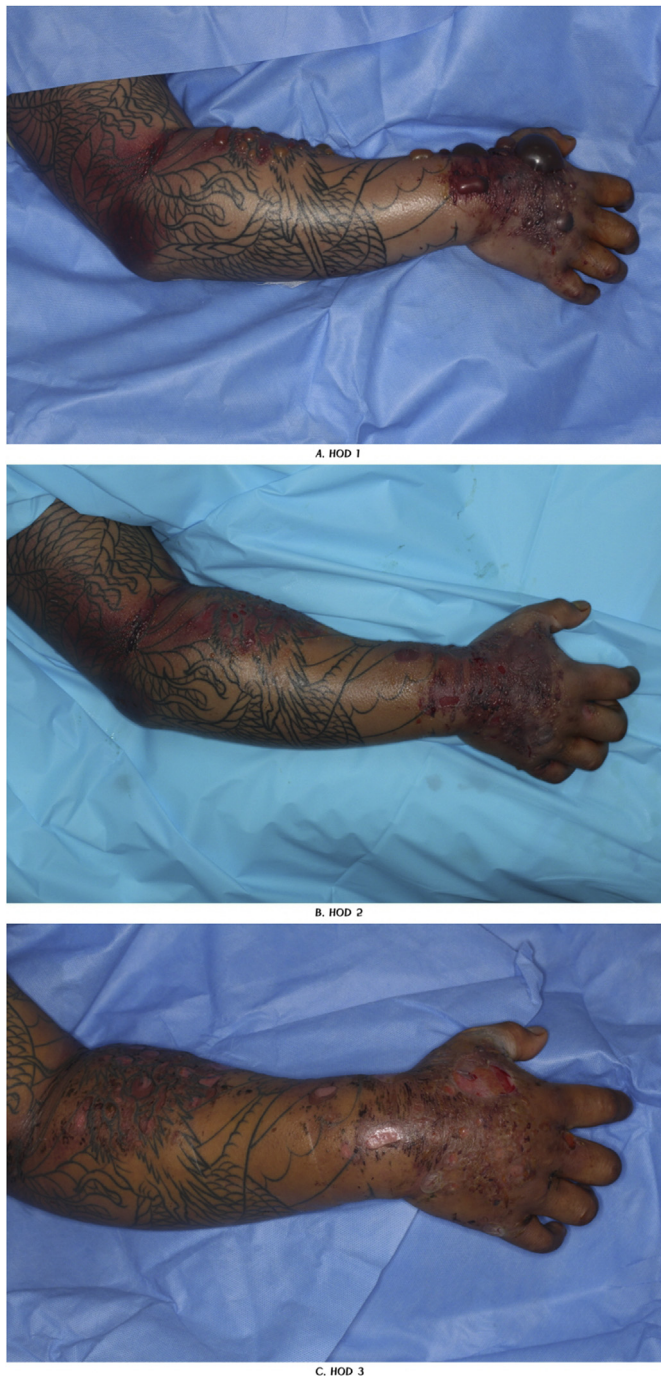Viperidae subfamily.<sup>4</sup>

The toxicity of the Gaboon viper venom clinically includes local tissue injury and VICC including disseminated intravascular coagulopathy like disorder, massive bleeding, hypotension, and cardiac toxicity.<sup>5–7</sup> Because victims bitten by the Gaboon viper are usually classified as an emergent patient, they immediately receive 5–10 vials of Gaboon viper antivenin according to the severity of envenomation.<sup>4,7</sup> In our case, the patient already presented local tissue injuries throughout the involved arm, VICC, and gross hematuria. Considering the cases of Gaboon viper envenomation in the literature,<sup>5–7</sup> the patient was presumed to have severe envenomation, which immediately required the antivenom for proper treatment. Unfortunately, to acquire the proper antivenom would have taken a protracted time. According to Meggs et al.,<sup>8</sup> the North American antivenom was efficacious to the Gaboon viper venom. The rattlesnake also belongs to the crotalinae subfamily. Theoretical cross-reactivity remains probable between Kovax<sup>®</sup> and the Gaboon viper venom.<sup>9,10</sup> Therefore, we decided to administer Kovax<sup>®</sup> to the patient. Considering that the snake venom is composed of various proteins, it is presumed that the neutralization of venom occurs through the cross-reaction of antivenin with similar components in each snake venom. The toxic symptoms and signs, including VICC, did not progress further following the



**Fig. 2. Changes of prothrombin time (PT) and activated partial thromboplastin time (aPTT) according to the administration of Kovax<sup>®</sup> and transfusions.** (HOD: hospital days, Plt: platelet, FFP: fresh frozen plasma)

Eight vials of antivenom, one unit of platelet and three units of fresh frozen plasma (FFP) were administered initially in the emergency department. Additional eight vials of antivenom were administered in the intensive care unit (ICU). Also, platelets, FFPs, and freeze-thaw preparations were transfused additionally during stay of the ICU. The patient was stabilized with time.



**Fig. 3.** Changes in local wound status according to the treatments (A: First hospital day, B: Second hospital day, C: Seventh hospital day). Swelling and hemorrhage remarkably improved with time.

administration of Kovax<sup>®</sup> and the patient gradually recovered from the envenomation over several days. We assumed that the administration of antivenom for the venom of another subfamily of snake treated the envenomation successfully through cross-neutralization.

We think that the followings should be considered in our case. First, the fact that illegitimate venomous snakes are easily imported through informal processes and the sales of the snake also made through informal channels is a clear threat to public health. Especially, if envenomation by the more venomous or neurotoxic snakes occurs, the death of the victims will be more likely. A strict and monitored quarantine process should be enacted. Second, we must consider stocking antidotes for deadly toxic nonindigenous animals and plants in medical care facilities. Toxic jellyfish and venomous sea snakes, which are recently observed in the domestic coasts of Korea, and poisonous scorpions, spiders and other reptiles such as cobras and rattlesnakes, will be problematic. Establishing an inventory of antidotes for potential exotic toxic organisms is important.

This is the first case report describing the successful recovery from Gaboon viper envenomation by the administration of Kovax<sup>®</sup>, and it might provide provisional clinical evidence for administering Kovax<sup>®</sup> in case of locally unavailable of timely administration of the Gaboon viper antivenom. Also, we hope that this case will be a basic step of establishing the pre-emptive strategies for exotic animal and plant envenomation.

#### Conflict of Interest

None declared.

#### References

- Minton SA. Bites by non-native venomous snakes in the United States. *Wilderness Environ Med.* 1996;7:297–303.
- Lim H, Kang HG, Kim KH. Antivenom for snake bite in Korea. *J Korean Med Assoc.* 2013;56:1091–1103.
- Marsh NA, Whaler BC. The Gaboon viper (*Bitis gabonica*): its biology, venom components and toxinology. *Toxicon.* 1984;22:669–694.
- Barceloux DG. *Medical Toxicology of Natural Substances: Foods, Fungi, Medicinal Herbs, Plants, and Venomous Animals.* Hoboken (NJ): John Wiley & Sons, Inc; 2008:1013–1073 Chapter 176, Terrestrial snakes.
- Brown R, Brasch L, Leichter D, Canfield D, Wolf M. Gaboon viper envenomation: an unexpected big-city emergency. *Pediatr Emerg Care.* 1989;5:248–249.
- Marsh N, Gattullo D, Pagliaro P, Losano G. The Gaboon viper, *Bitis gabonica*: hemorrhagic, metabolic, cardiovascular and clinical effects of the venom. *Life Sci.* 1997;61:763–769.
- Marsh N, DeRoos F, Touger M. Gaboon viper (*Bitis gabonica*) envenomation resulting from captive specimens—a review of five cases. *Clin Toxicol (Phila).* 2007;45:60–64.
- Meggs WJ, Wiley CN, Brewer KL, Hack JB. Efficacy of North American crotalid antivenom against the African viper *bitis gabonica* (Gaboon viper). *J Med Toxicol.* 2010;6:12–14.
- Isbister GK, Maduwage K, Page CB. Antivenom cross neutralisation in a suspected Asian pit viper envenoming causing severe coagulopathy. *Toxicon.* 2014;90:286–290.
- Leong PK, Tan NH, Fung SY, Sim SM. Cross neutralisation of Southeast Asian cobra and krait venoms by Indian polyvalent antivenoms. *Trans R Soc Trop Med Hyg.* 2012;106:731–737.