



Case Report

Treating acute hypertensive cardiogenic pulmonary edema with high-dose nitroglycerin

Yi-Ting Hsieh^a, Tai-Ying Lee^a, Jui-Shih Kao^a, Hsin-Lin Hsu^a, Chee-Fah Chong^{a, b, *}^a Emergency Department, Shin-Kong Wu Ho-Su Memorial Hospital, Taipei City, Taiwan^b School of Medicine, Fu Jen Catholic University, New Taipei City, Taiwan

ARTICLE INFO

Article history:

Received 12 December 2017

Received in revised form

11 January 2018

Accepted 12 January 2018

Available online 2 February 2018

Keywords:

Pulmonary edema

Nitroglycerin

Emergency department

ABSTRACT

Acute pulmonary edema due to sympathetic surge and increased peripheral vascular resistance often present to the emergency department (ED) with markedly elevated blood pressure, severe dyspnea, and desaturation. This condition is known as “SCAPE” (sympathetic crashing acute pulmonary edema). We present three SCAPE patients who were successfully treated with high-dose nitroglycerin (NTG) and bilevel positive airway pressure (BiPAP) ventilation. All three patients presented with respiratory failure on arrival but rapidly improved after treatment and did not require endotracheal intubation or admission to the intensive care unit (ICU). SCAPE patients usually present to the ED with extreme respiratory distress associated with diaphoresis, restlessness, and high blood pressure. Emergency physicians must know how to manage SCAPE with high-dose nitrates and NIPPV (noninvasive positive pressure ventilation) because, when treated promptly, one will not only save a life but also obviate the need for endotracheal intubation and ICU admission.

Copyright © 2018 The Emergency Medicine Association of Turkey. Production and hosting by Elsevier B.V. on behalf of the Owner. This is an open access article under the CC BY-NC-ND license (<http://creativecommons.org/licenses/by-nc-nd/4.0/>).

1. Introduction

Organic nitrates, such as nitroglycerin (NTG), isosorbide-5-mononitrate and isosorbide dinitrate, are strong vasodilators traditionally used in the treatment of patients with congestive heart failure, acute coronary syndrome, or severe hypertension.¹ Patients with acute congestive heart failure complicated with pulmonary edema often present to the emergency department (ED) with markedly elevated blood pressure, severe dyspnea, and desaturation. Such respiratory emergencies are the result of a sympathetic surge with markedly increased peripheral vascular resistance. This condition is known as “SCAPE” (sympathetic crashing acute pulmonary edema).² We present three SCAPE patients who were successfully treated with high-dose nitroglycerin (NTG) and bilevel positive airway pressure (BiPAP) ventilation. All

three patients presented with respiratory failure on arrival but rapidly improved after treatment and did not require endotracheal intubation or admission to the intensive care unit (ICU). High-doses of NTG are well tolerated in our patients. Recent studies also demonstrate that nitrate tolerance may be the result of supra-physiological and suprapharmacological NTG doses. On the other hand, low doses of NTG are less likely to induce tolerance¹.

2. Case presentations

2.1. Case 1

A 65-year-old female with past history of heart failure and hypertension presented to the ED with acute dyspnea and chest tightness. On examination, she appeared anxious and diaphoretic. Her BP was 213/91 mm Hg, PR 103 bpm, RR 36/min, SpO₂ 92% (using high-flow O₂ mask), and temperature 36 °C. Orthopnea and bilateral basal rales were also noted. ECG showed sinus tachycardia with nonspecific ST-T changes. Chest X-ray and bedside ultrasound are diagnostic of acute pulmonary edema. Blood tests were unremarkable. BiPAP ventilation was initiated immediately after 3 consecutive tablets of sublingual NTG (NITROSTAT 0.6 mg/tab) were given without success. The patient continued to have

* Corresponding author. Emergency Department, Shin-Kong Wu Ho-Su Memorial Hospital, No.95 Wen-Chang Road, Shi-Lin District, Taipei City 111, Taiwan.

E-mail addresses: yiting.hsieh96@gmail.com (Y.-T. Hsieh), eclipsewing@hotmail.com (T.-Y. Lee), smileyalice1224@gmail.com (J.-S. Kao), maggieq0604@gmail.com (H.-L. Hsu), m002202@ms.skh.org.tw (C.-F. Chong).

Peer review under responsibility of The Emergency Medicine Association of Turkey.

dyspnea, diaphoresis and markedly elevated BP (223/100 mm Hg). Push-doses (1 mg every 2 minutes) of intravenous NTG were administered, followed by IV NTG low-dose infusion at 40 $\mu\text{g}/\text{min}$. After receiving a total dose of 6 mg NTG boluses over 15 minutes, her vital signs normalized (BP 135/86 mm Hg, PR 88 bpm) and we were able to discontinue the BiPAP machine. The patient was admitted to the general ward and was later confirmed to have congested heart failure. After admission, she was treated with furosemide and digoxin with good response and was discharged several days later (see Fig. 1).

2.2. Case 2

A 60-year-old male with history of hypertension, diabetes, and end-stage renal disease under regular hemodialysis, presented to our ED with severe shortness of breath for several hours. On arrival, his vital signs were BP 205/105 mm Hg, PR 116 bpm, RR 30/min, temperature 36 °C, and SpO₂ 89% (at room air). Physical examination revealed bilateral wheezing and basal rales. Pulmonary edema was confirmed on chest radiograph. The dyspnea deteriorated despite high-flow oxygen use and 3 subsequent tablets of NTG given sublingually. He was rapidly connected to a BiPAP machine and 4 consecutive push-doses (1 mg every 2 minutes) of IV NTG were given until the dyspnea subsided. Shortly after the NTG boluses, his BP was lowered to 140/82 mm Hg and he was able to come off the BiPAP machine. Hemodialysis was scheduled 4 hours after his arrival and he was discharged uneventfully after the dialysis (see Fig. 2).

2.3. Case 3

A 65-year-old male presented to the ED with progressive dyspnea and profuse sweating. He had HTN, DM, and ESRD with regular dialysis. His vital signs were BP 198/86 mm Hg, PR 143 bpm, RR 36/min, SPO₂ 60%, and temperature 35 °C (at room air). Physical examination showed bilateral moist rales and chest radiograph confirmed lung edema. ECG showed sinus tachycardia and blood tests were unremarkable. Treatment with high-flow oxygen and 3 sublingual NTG was unsuccessful. Subsequently, BiPAP and 3 boluses of NTG (1 mg every 2 minutes) successfully stabilized the

patient and prevented the need of endotracheal intubation. The patient's vital signs stabilized (BP 141/89, PR 98) prior to hemodialysis and he was able to breath smoothly (RR 18/min, SpO₂ 96%) through O₂ nasal prongs. He was discharged uneventfully after hemodialysis (see Fig. 3).

3. Discussion

Life-threatening acute pulmonary edema may not be caused by fluid accumulation but rather fluid redistribution because of heart failure and increased systemic vascular resistance from sympathetic neurohormonal activation. Previous studies also demonstrated that the vasoconstriction can be prevented by angiotensin I-converting enzyme inhibitor (e.g. captopril), suggesting that this phenomenon is mediated by angiotensin II.³ The activation of renin-angiotensin-aldosterone system (RAAS) results in even higher peripheral vascular resistance and increased sodium and water reabsorption. Both worsen cardiac function and decrease pulmonary venous return. As a result, intravascular fluid shift into the pulmonary interstitium and alveoli, causing hypoxia, dyspnea, and further sympathetic surge.^{2,4} Therefore, sympathetic crashing acute pulmonary edema (SCAPE) is a better terminology for this subset of patients.^{2,4,5}

In SCAPE, the abrupt redistribution of fluid into the lungs may occur even when the patient is hypovolemic or euvolemic. Therefore, the emphasis in treating pulmonary edema has shifted from diuretics to vasodilators, especially high-dose nitrates, combined with noninvasive positive pressure ventilation (NIPPV).^{2,6,7} When treated promptly, patients with SCAPE will recover rapidly. More importantly, many unnecessary intubations and ICU admissions could be avoided by the high-dose NTG bolus approach. Conventionally, the usual dose of NTG in treating congestive heart failure (CHF) is 5–40 $\mu\text{g}/\text{min}$ continuous infusion. For doses <250 $\mu\text{g}/\text{min}$, the effects NTG are predominantly venodilatory causing preload reduction. In treating CHF patients with profound hypertension and lung edema, NTG doses should exceed 250 $\mu\text{g}/\text{min}$ in order to take effect (MAP reduction and fluid redistribution) rapidly via venous and arterial dilation.⁷ In our protocol, high-dose NTG and BiPAP are the mainstay of treatment which should be started within minutes of the patient's arrival to the ED. Our NTG dosing protocol include

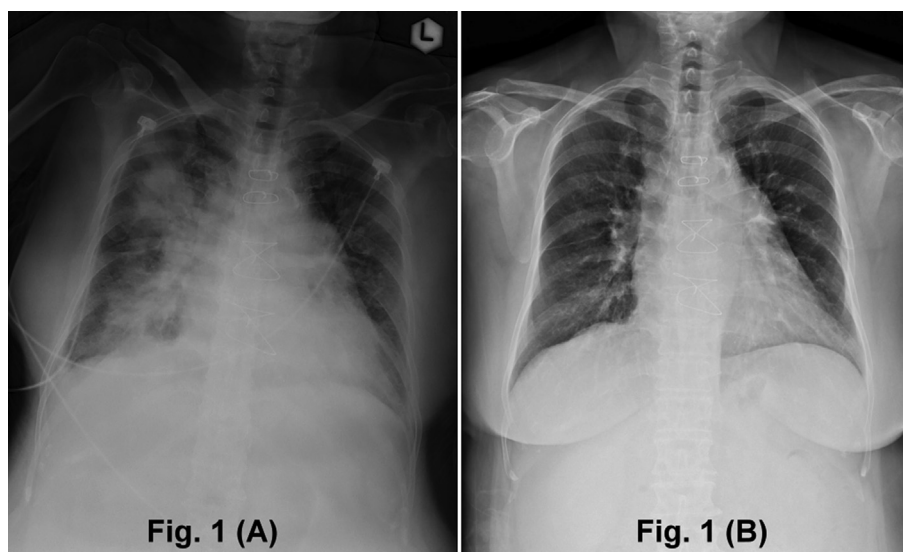


Fig. 1. Case 1: chest radiograph showing features of bilateral perihilar edema at presentation (A) and resolution of pulmonary edema after treatment with nitroglycerin and diuretics (B).

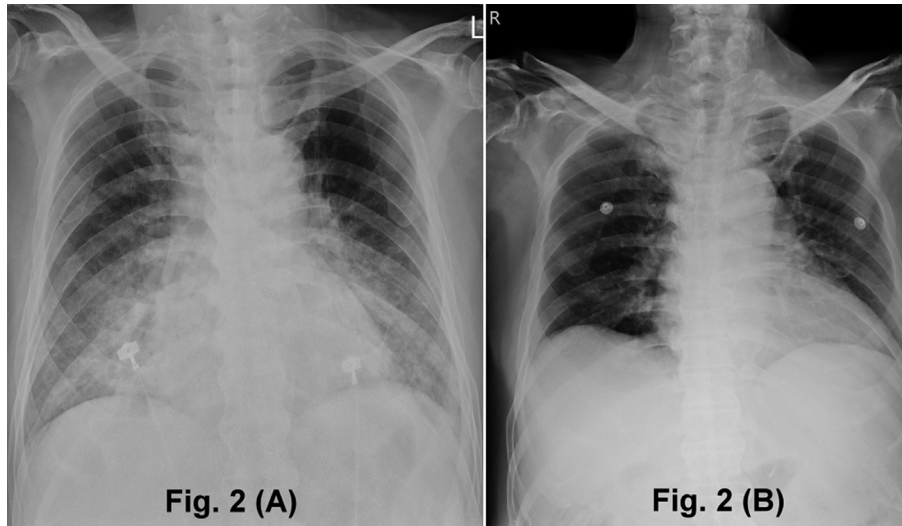


Fig. 2. Case 2: chest radiograph showing features of bilateral alveolar edema at presentation (A) and resolution of pulmonary edema after treatment with nitroglycerin and hemodialysis (B).

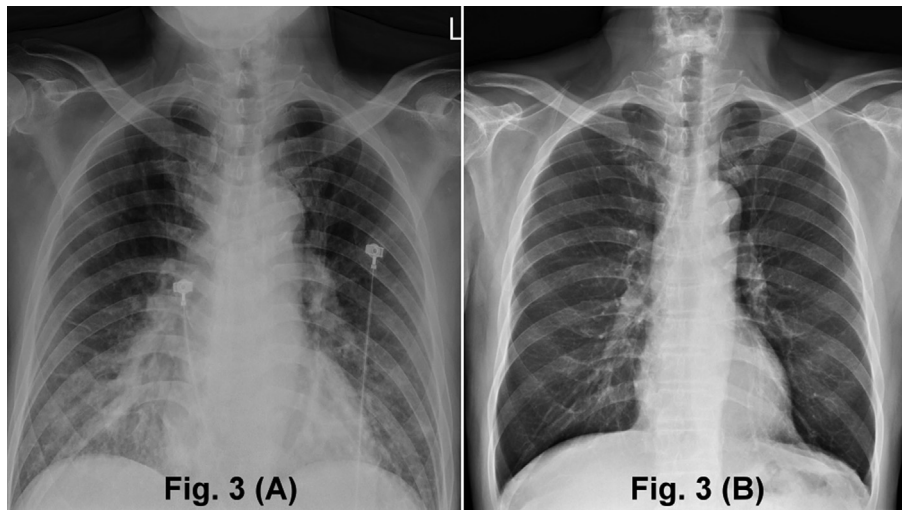


Fig. 3. Case 3: chest radiograph showing features of bilateral interstitial edema at presentation (A) and resolution of pulmonary edema after treatment with nitroglycerin and hemodialysis (B).

0.6 mg sublingual tablet up to 3 times followed by 1 mg intravenous boluses every 2 minutes as needed, up to 10 mg maximum. Contraindications to NTG use include severe aortic stenosis, recent use of phosphodiesterase type 5 inhibitors (e.g. sildenafil, tadalafil, vardenafil), hypertrophic obstructive cardiomyopathy, or hypotension at any time.^{6,7}

4. Conclusion

In conclusion, our cases demonstrated that SCAPE patients usually present to the ED with extreme respiratory distress associated with diaphoresis, restlessness, and high blood pressure (usually SBP > 180 mm Hg). Emergency physicians must know how to manage SCAPE with high-dose nitrates and NIPPV because, when treated promptly, one will not only save a life but also obviate the need for endotracheal intubation and ICU admission. Future prospective, randomized, multi-center trials are warranted to confirm the SCAPE hypothesis.

Funding/Conflict of interest

None.

References

- Münzel T, Daiber A, Gori T. More answers to the still unresolved question of nitrate tolerance. *Eur Heart J.* 2013;34:2666–2673.
- Naman A, Akshay K, Praveen A, Nayer J. Sympathetic crashing acute pulmonary edema. *Indian J Crit Care Med.* 2016;20:719–723.
- Heitzer T, Just H, Brockhoff C, et al. Long-term nitroglycerin treatment is associated with supersensitivity to vasoconstrictors in men with stable coronary artery disease: prevention by concomitant treatment with captopril. *J Am Coll Cardiol.* 1998;31:83–88.
- Cotter G, Kaluski E, Moshkovitz Y, et al. Pulmonary edema: new insight on pathogenesis and treatment. *Curr Opin Cardiol.* 2001;16:159–163.
- Ware LB, Matthay MA. Clinical practice. Acute pulmonary edema. *N Engl J Med.* 2005;353:2788.
- Levy P, Compton S, Welch R, et al. Treatment of severe decompensated heart failure with high-dose intravenous nitroglycerin: a feasibility and outcome analysis. *Ann Emerg Med.* 2007;50:144–152.
- Wilson SS, Kwiatkowski GM, Millis SR, et al. Use of nitroglycerin by bolus prevents intensive care unit admission in patients with acute hypertensive heart failure. *Am J Emerg Med.* 2017;35:126–131.