

Contents lists available at [ScienceDirect](http://www.elsevier.com/locate/TJEM)

# Turkish Journal of Emergency Medicine

journal homepage: <http://www.elsevier.com/locate/TJEM>

## Case Report

# Scorpion-related cardiomyopathy and acute pulmonary edema in a child who is stung by *Leiurus abduallahbayrami*



Mehmet Dokur <sup>a,\*</sup>, Mustafa Dogan <sup>b</sup>, Ersen Aydin Yagmur <sup>c</sup>

<sup>a</sup> Necip Fazil City Hospital, Department of Emergency Medicine, 46050, Dulkadiroglu, Kahramanmaraş, Turkey

<sup>b</sup> Pamukkale University School of Medicine, Department of Pediatrics, Kinikli Campus, 20070, Denizli, Turkey

<sup>c</sup> Manisa Celal Bayar University Alasehir Vocational High School, 45600, Alasehir, Manisa, Turkey

## ARTICLE INFO

### Article history:

Received 12 October 2016

Received in revised form

21 December 2016

Accepted 23 December 2016

Available online 18 March 2017

### Keywords:

Leiurus

Scorpionism

Cardiomyopathy

Pulmonary edema

## ABSTRACT

Venom of *Leiurus abduallahbayrami* (Scorpiones: Buthidae) is an extremely toxic one and it stimulates voltage-gated sodium and potassium channels. In case of a sting by this scorpion; excessive catecholamine release occur and it impairs left ventricle contractility and consequently a heart failure occurs (scorpion sting-related cardiomyopathy). In addition to this cardiac-induced acute pulmonary, edema may occur in severe cases too. An 11-year-old male child who was stung by a scorpion (species: *Leiurus abduallahbayrami*) consulted to the Emergency Room. Even after 7 h of scorpion envenomation he was confused and having hallucinations. Besides he was dyspneic, tachycardic, hypotensive and got worse in overall situation due to cardiogenic pulmonary edema. These clinical findings are concordant with the Level III scorpion envenomation (major systemic manifestations). Positive inotropic agents, diuretics and antiagregant agents used on supportive therapy in his treatment. After 2 weeks he get recovered and discharged from the pediatric intensive care unit. This research is conducted by thinking emergency physicians should learn that *Leiurus abduallahbayrami* envenomation can cause scorpion-related cardiomyopathy and acute pulmonary edema especially in children.

Copyright © 2017 The Emergency Medicine Association of Turkey. Production and hosting by Elsevier B.V. on behalf of the Owner. This is an open access article under the CC BY-NC-ND license (<http://creativecommons.org/licenses/by-nc-nd/4.0/>).

## 1. Introduction

Although scorpions live all over the world, scorpion envenomation generally observed as an important emergency health problem in tropical and subtropical countries especially in spring, summer and autumn seasons.<sup>1</sup> According to this constraints 2.3 billion of the world population is at risk. The annual occurrence of scorpion stings exceeds 1.2 million nowadays and these stings caused more than 3250 casualty (0.27%).<sup>2</sup> Scorpion envenoming may cause multiorgan insufficiency, neurotoxicity and cardiotoxicity in the affected people and it may be deadly, especially for children.<sup>1,3</sup>

*Leiurus abduallahbayrami* (Scorpiones:Buthidae; previously identified as *Leiurus quinquestriatus* which is endemic in

southeastern parts of Turkey and northern part of Syria) was classified as a new *Leiurus* species<sup>4</sup> and its venom contains several low-molecular weight neurotoxic proteins that act mainly on two classes of ion channels: the sodium and potassium voltage-gated channels and caused by the massive release in catecholamines (catecholamines storm) due to sting a severe alteration gets induced on Left Ventricle (LV) contractility (scorpion-related cardiomyopathy). Not only scorpion-related cardiomyopathy but also increased pulmonary capillary permeability sourced from excessive stimulation of alpha receptors are advocated to be the underlying cause of pulmonary edema following scorpion envenomation.<sup>5,6</sup> Children are also more susceptible to these effects. Serious cases require follow-up in Pediatric intensive care unit (ICU).<sup>1</sup> Specific scorpion antivenom (SAV) therapy and optimal supportive care is recommended for all kinds of patients. Dopamine and dobutamine is used in the treatment of scorpion-related cardiomyopathy. Alpha-blockers, like betablockers, might be beneficial catecholamines during the early periods of scorpion envenomation.<sup>3,5,6</sup> In treatment of pulmonary edema arising from scorpion envenomation the same principles as those for the treatment of cardiogenic pulmonary edema shall be followed.

\* Corresponding author. Tel.: +90 344 2282800; fax: +90 344 2515103.

E-mail addresses: [drdokur@gmail.com](mailto:drdokur@gmail.com) (M. Dokur), [mustafad42@gmail.com](mailto:mustafad42@gmail.com) (M. Dogan), [ersen.yagmur@gmail.com](mailto:ersen.yagmur@gmail.com) (E.A. Yagmur).

Peer review under responsibility of The Emergency Medicine Association of Turkey.

On this study we described a pediatric case of cardiogenic acute pulmonary edema that was associated with *Leiurus abduallahbayrami* envenomation (Level III, according to the recommendations of the Scorpion Consensus Expert Group).<sup>7</sup>

## 2. Case presentation

An 11-year-old male child was consulted to the Emergency Room (ER) with the complaint of scorpion sting on a countryside of Kilis province (in southeastern of Turkey) at 5 p.m. in the month of June. The time elapsed until the admission was about 1 hour and two different parts of the patient's body get stung by scorpion (left gluteal and left pectoral regions). Species of scorpion was determined as *Leiurus abduallahbayrami* (Fig. 1). The length and weight measurements of this child were recorded as 133 cm and 27 kg respectively (BSA: 1.01 m<sup>2</sup>, Dubois). At first, on medical examination he was anxious and lethargic but no comatose (Glasgow Coma Scale score-GCS of 12 on a scale from 3 to 15) observed and both pupils were dilated (pupillary diameter was approximately 3–4 mm.) and isochoric. Pupillary light reflex (direct and indirect) were positive. Also no signs of cranial and/or nerve involvement observed. He was tachycardic (HR was 140/min, regular) and his arterial blood pressure (BP) was slightly elevated (NIBP: 100/103 mmHg) and slightly tachypneic (Respiratory rate: 22/min, regular) and a few crackles heard during auscultation. He was pale, but there was no cyanosis (O<sub>2</sub> saturation: 91.4%, pH: 7.33, PO<sub>2</sub>: 65.6 mmHg, PCO<sub>2</sub>: 35.7 mmHg, HCO<sub>3</sub>: 18.9 meq/L and BE<sub>ecf</sub>: -6.1) and he was given oxygen with oxygen mask (6 L/min). Body temperature was normal (36.5 °C). In addition, there was nausea and diaphoresis but emesis is not observed. These clinical findings were concordant with the Level II scorpion envenomation (minor systemic manifestations).<sup>7</sup> So, in the treatment of this patient the liquid supplementation crystalloid solutions (Isolyte-P<sup>®</sup> solution administrated as 20 mg/kg) were preferred and following the skin test SAV was administered (5 mL/30 min, IV infusion). The patient was transferred into Pediatric ICU. Clinical findings in the early hours of monitoring in Pediatric ICU resulted a thought that the first symptoms of the envenomation is continuing. However, in the later hours patient's anxiety, cold diaphoresis and tachycardia increased due to respiratory distress and hemodynamic impairment. Approximately seven hours after admission to ER he was dyspneic and got worse in overall situation in spite of supportive and symptomatic treatments applied during this period. So, on medical examination he was confused and had hallucinations (GCS score of 9 on a scale from 3 to 15). He was tachypneic (RR: 48/min)



Fig. 1. *Leiurus abduallahbayrami* (Scorpiones: Buthidae).

and intercostal-subcostal retractions and bilateral crepitant crackles in her lung bases observed. He was seriously tachycardic (HR: 170/min/rhythmic) and hypotensive (NIBP: 60/40 mmHg). Besides, S3 was heard on cardiac auscultation. A cyanosis situation is observed (O<sub>2</sub> saturation: 82%) and he was given oxygen with oxygen mask (10 L/min) despite of the situation he was not in need of endotracheal intubation and artificial respiratory support. Femoral pulses could be checked and liver was palpable on 5–6 cm through the midclavicular line. Laboratory examination findings were as follows; WBC level is increased (21900  $\mu$ l), AST and ALT levels were high (135 U/L and 46 U/L respectively) and blood glucose level was 205mg/dL. Posterior-anterior Chest x-ray revealed findings of cardiogenic pulmonary edema (Chest x-ray of the patient was taken by a portable roentgen machine while he was in seated position on stretcher) (Fig. 2). Echocardiographic examination was performed immediately afterwards and it revealed that the left ventricular cavity was dilated with 1st degree mitral and tricuspid valves insufficiency secondary to annulus dilatation (FS = 17.08% [range for pediatric fractional shortening (FS): 28%–44%] and EF = 35.63% [range for pediatric ejection fraction (EF): 56%–78%], Fig. 3a and b). At this stage, clinical findings of this patient became concordant with the Level III (major systemic manifestations)<sup>7</sup> scorpion envenomation. Next treatment plan of this case has continued focusing on acute pulmonary edema and cardiac failure. So, he was administered dopamine (10  $\mu$ g/kg/min, IV infusion), dobutamine (10  $\mu$ g/kg/min, IV infusion), furosemide (2 mg/kg/day, IV), enalapril (0.1 mg/kg/day, per-oral), digoxine gtt. (0.15 mg/day, per-oral) and morphine sulphate (0.2 mg/kg/single dose, IV slowly). After 24 hours, difficulty of respiration decreased and findings of insufficiency regressed but left dorsalis pedis, tibialis and posterior pulses could not be checked. Still there were acrocyanosis and coldness in distal parts of the extremities. So, a significant decrease was determined in artery flow rate at lower extremity doppler ultrasonography. But neither intracardiac mass nor thrombus found with simultaneously made control echocardiography. For this reason an antiaggregant drug (acetylsalicylic acid, 4 mg/kg/day, per-oral), an antithrombotic drug HMWH (enoksaparin sodyum: 2 mg/kg/day, SC) and pentoxifylline (in 200 cc Rheomacrodex<sup>®</sup> solution, IV infusion/10 hours with total 3-days treatment) were added to his treatment. Peripheric pulse values could normally be checked after 48 hours of hospitalisation. Moreover pulmonary

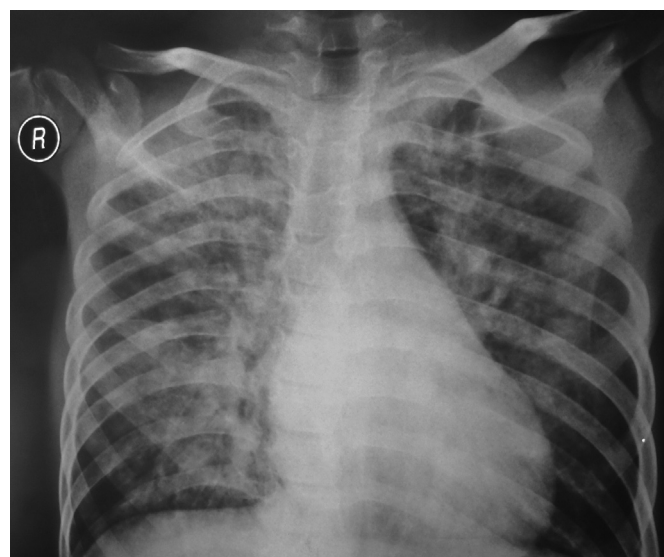
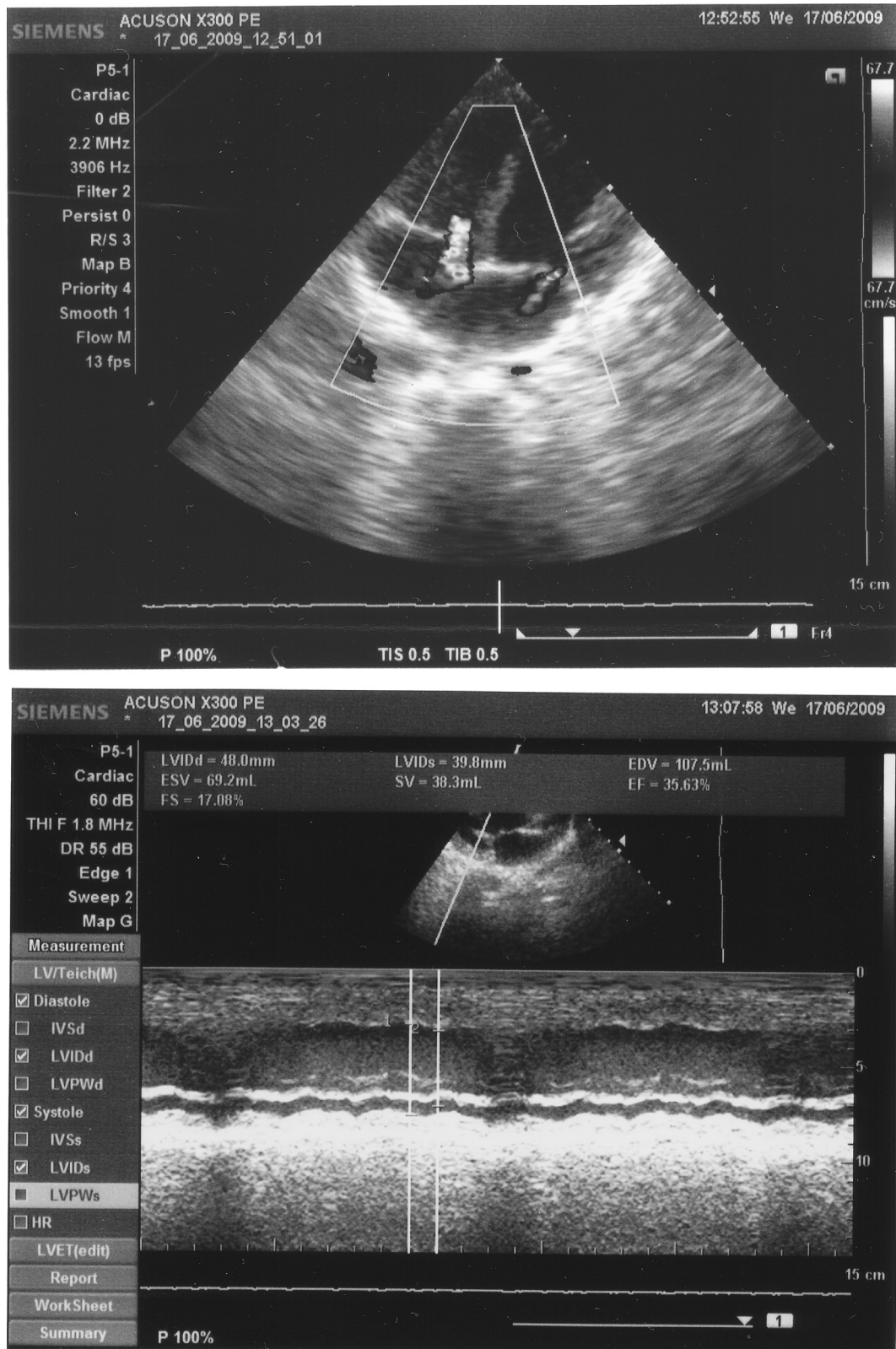


Fig. 2. Acute pulmonary edema (after 7 h of *Leiurus abduallahbayrami* envenomation).

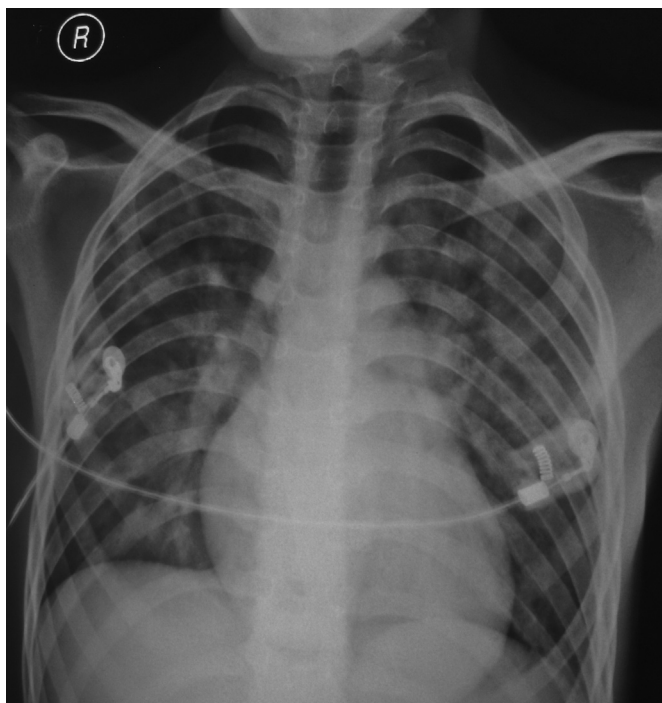




**Fig. 3.** a. Regurgitation in Mitral and Tricuspid valves on Doppler echocardiography, b. Decreased FS and EF measurements on normal M-Mode echocardiography.

edema was decreased to a large extent (Fig. 4). In this period, an arrhythmia or dysrhythmia due to the use of morphine sulfate was not detected. Patients who is hemodynamically better transferred from Pediatric ICU to Pediatric inpatient clinic. His

echocardiographic EF/FS values returned to normal rates after 7 days of hospitalisation. Dopamine and dobutamine infusions were gradually decreased and stopped. On the 10th day of the treatment antithrombotic treatment concluded as well. He was externed on



**Fig. 4.** Significant healing on chest X-ray findings (after 18 hours of *Leiurus abdullahbayrami* envenomation).

the 14th day of hospitalisation with oral enalapril and furosemide treatments and to be called for outpatient treatment controls. After 30 days of his hospitalisation his findings became normal in the control echocardiographic examination. Hence, he get called for control after 2 months.

### 3. Discussion

Scorpion envenomation still is an important environmental health problem in tropical and subtropical regions. Many species of scorpions have been identified in the whole world and some of these species causes morbidity and mortality.<sup>1–3</sup> In recent years *Leiurus abdullahbayrami* has been classified as a new *Leiurus* species from its natural habitat in southeastern regions of Turkey.<sup>4</sup> Venom of *Leiurus abdullahbayrami* stimulates sodium and potassium voltage-gated ion channels and this causes excessive catecholamine release through the stimulation of sodium and potassium ion channels. This leads to excessive catecholamine release (catecholamines storm). Excessive catecholamine release impairing LV contractility causes heart failure (scorpion-related cardiomyopathy). As a result, cardiac-induced acute pulmonary edema occurs in severe cases.<sup>5,6</sup> Especially children are at greater risk than adults. This can be explained with the fact that small children or infants are hemodynamically be more unstable and vulnerable than adults. In addition small children and infants are at high risk in term of morbidity and mortality.<sup>1,8</sup> Moreover since they are not able to protect themselves against the environmental dangers and since their awareness level is lesser than adults their morbidity and mortality rates can go significantly higher. For these reasons these risk groups can get stunged from multiple parts of their body by scorpions. Having a lower weight than the other humans around, has created an extra risk for this case. So, this case is a typical example for this situation.

The first clinical findings of our case in the emergency room was consistent with Level II scorpion envenomation (minor systemic

manifestations) but after 7 h it turned into Level III scorpion envenomation (major systemic manifestations).<sup>7</sup> This might indicate that venom of *Leiurus abdullahbayrami* is extremely toxic. Scorpion toxicity may vary due to different reasons. But in our case it is revealed that minor systemic symptoms start to occur within a period of 1–2 hours and major systemic symptoms occur within a period of 4–6 hours. Moreover, during clinical follow-up of the cases it also attracted our attention as the most important point; a high sympathetic activity observed all the time. This can be explained by massive catecholamine release following the envenomation due to the sting of *Leiurus abdullahbayrami* species.<sup>5</sup> This may be important in determining the prognosis of scorpion victims. The serious loss of consciousness and epileptic attacks is appeared to be important clinical signs in our case. This may be a proof that at the forefront of hemodynamic impairment than neurological in *Leiurus abdullahbayrami* envenomations. Hematological and biochemical parameters impaired in severe scorpion envenomations (Level III+). Among these; WBC and platelets and glucose, AST and ALT elevation in blood are known.<sup>3,9</sup> This may be due to the increased sympathetic activation and venom's toxic effects. Haematological and biochemical findings were consistent with the literature but these laboratory examination findings are not progressive. According to Mishra et Prasad; echocardiography should be preferred routinely in all patients with grade 2–4 envenomation to predict outcome and discharge the patients from hospital accordingly.<sup>8</sup> Echocardiographic findings in our case was also played a crucial role in determining recovery and discharge from Pediatric ICU and hospital. According to current literature anti-venom therapy is recommended to patients after the scorpion stings.<sup>5,6,9</sup> After the scorpion stings, applying standard dose SAV did not affect enough on the clinical course of the case. The reason for this can be; the SAV that is used, currently not be effective enough on progressive *Leiurus abdullahbayrami* envenomation. The use of positive inotropic agents for cardiogenic pulmonary edema is recommended.<sup>1,3,5,6,9</sup> Adding alpha and beta-blocker agents to this treatment has been proposed in the current literature. The reason for this can be explained with excessive stimulation (alpha receptor overstimulation) of the sympathetic nervous system by the scorpion venom.<sup>10</sup> Alpha receptor overstimulation can be associated with excessive sympathetic activity findings (agitation, tachycardia, tachypnea, excessive diaphoresis and piloerection etc.) that is accompanied with impaired hemodynamics. Despite the severe sympathetic stimulation findings we focused on the solution of hemodynamic problems in this case. Because we believed that these treatments will be effective (positive inotropic therapy with supportive therapy). So, we preferred mostly hemodynamics solution focused therapeutic modality in this case and during his treatment usage of prazosin or doxazosin was not needed. In addition to the treatment we preferred using single dose of morphine sulfate in order to benefit from anti-edema effect and enhancing effect on compliance of the lung in acute cardiogenic pulmonary edema and reducing effect of scorpion venom-induced sympathetic overstimulation. We also used antiplatelet drug and antithrombotic drug to protect the patient from peripheral arterial occlusion. According to our study, length of stay in ICU and length of stay in hospital should at least be 48–72 hours and 7–10 days respectively to obtain the adequate response to treatment of scorpion related diseases (Level II+) in children. In this study duration of monitoring in ICU and length of stay in hospital were consistent with current literature.<sup>1,3,8,9</sup>

### 4. Conclusion

Although *Leiurus abdullahbayrami* became classified a few years ago it is especially dangerous for children. Following the scorpion

sting, resulting clinical manifestations are scorpion-related cardiomyopathy and acute pulmonary edema with sympathetic overstimulation. The pathophysiology of scorpion envenomation is based on the affection of ion channels by low molecular weight venom proteins. So, catecholamines storm with severe alteration in LV contractility (scorpion-related cardiomyopathy) and increased pulmonary capillary permeability (acute pulmonary edema) are the dramatic results of scorpion envenomation. Level II and III of scorpion envenomation in children shall be monitored in Pediatric ICU. Positive inotropic agents and alpha and beta blocker agents with supportive therapy are recommended in the treatment.

#### Conflicts of interest

None declared.

#### References

1. Bahloul M, Chabchoub I, Chaari A, et al. Scorpion envenomation among children: clinical manifestations and outcome (analysis of 685 cases). *Am J Trop Med Hyg.* 2010;83:1084–1092.
2. Chippaux JP, Goyffon M. Epidemiology of scorpionism: a global appraisal. *Acta Trop.* 2008;107:71–79.
3. Isbister GK, Bawaskar HS. Scorpion envenomation. *N Engl J Med.* 2014;371:457–463.
4. Ozkan O, Yagmur EA, Ark M. A newly described scorpion species, *Leiurus abduhbayrami* (Scorpion: *buthidae*), and the lethal potency and in vivo effects of its venom. *J Venom Anim Tox Incl Trop Dis.* 2011;17:414–421.
5. Abroug F, Souheil E, Ouane I, et al. Scorpion-related cardiomyopathy: clinical characteristics, pathophysiology, and treatment. *Clin Toxicol.* 2015;53:511–518.
6. Bahloul M, Chaari A, Dammak H, et al. Pulmonary edema following scorpion envenomation: mechanisms, clinical manifestations, diagnosis and treatment. *Int J Cardiol.* 2013;162:86–91.
7. Khattabi A, Soulaymani-Bencheikh R, Achour S, et al. Scorpion Consensus Expert Group. Classification of clinical consequences of scorpion stings: consensus development. *Trans R Soc Trop Med Hyg.* 2011;105:364–369.
8. Mishra OP, Prasad R. Myocardial dysfunction in children with scorpion sting envenomation. *Indian Pediatr.* 2015;52:291–292.
9. Cupo P. Clinical update on scorpion envenoming. *Rev Soc Bras Med Trop.* 2015;48:642–649.
10. Peker E, Oktar S, Dogan M, et al. Prazosin treatment in the management of scorpion envenomation. *Hum Exp Toxicol.* 2010;29:231–233.