



Case Report

A rare cause of acute abdominal pain in children: Isolated tubal torsion; a case series



Yasemin Dere Gunal ^{a,*}, Gokhan Berktug Bahadir ^b, Ozlem Boybeyi ^c, Aylin Pelin Cıl ^d, Mustafa Kemal Aslan ^a

^a Kırıkkale University, Department of Pediatric Surgery, Kırıkkale, Turkey

^b Mersin University, Department of Pediatric Surgery, Mersin, Turkey

^c Hacettepe University, Department of Pediatric Surgery, Ankara, Turkey

^d Kırıkkale University, Department of Obstetrics and Gynecology, Kırıkkale, Turkey

ARTICLE INFO

Article history:

Received 15 July 2016

Received in revised form

9 November 2016

Accepted 23 December 2016

Available online 31 December 2016

Keywords:

Fallopian tube

Torsion

Paratubal cyst

Adolescent

Acute abdomen

ABSTRACT

Isolated tubal torsion -a rare cause of acute abdomen in children-is usually difficult to diagnose because of non-specific findings. Surgical salpingectomy is required in delayed diagnosis in most cases. Three sexual inactive adolescents diagnosed in isolated tubal torsion (ITT) were discussed for its diagnostic features and surgical management. Laboratory tests and radiological studies including ultrasonography (US), color doppler ultrasound were performed in all patients after evaluation for acute lower abdominal pain in emergency department and they underwent surgical intervention with laparotomy (n:2) and laparoscopy (n:1). One of the patients in this study had salpingectomy. Detorsion of the fallopian tube and cyst excision were performed in the remaining two patients who also had paratubal cysts. There was no recurrence in these patients during the follow-up for 3 and 2 years. The isolated tubal torsion should be kept in mind and early surgical management is essential in order to preserve fallopian tube because of its importance in fertility.

Copyright © 2016 The Emergency Medicine Association of Turkey. Production and hosting by Elsevier B.V. on behalf of the Owner. This is an open access article under the CC BY-NC-ND license (<http://creativecommons.org/licenses/by-nc-nd/4.0/>).

1. Introduction

Adnexal torsion is one of the most important causes of acute abdominal pain and requires prompt surgical treatment.¹ Although adnexal torsion including ovary with or without fallopian tube is a common condition, isolated torsion of fallopian tube without an ovarian torsion is extremely rare, with an incidence of 1 in 1.5 million women.¹ The incidence is considerably uncommon in the pediatric and adolescent population.^{1,2}

Since the clinical and imaging findings for ITT are non-specific, the diagnosis of ITT can be challenging.^{1–3} In most cases, surgical salpingectomy is the choice of treatment because of delayed diagnosis. Nevertheless, there are very few cases managed with detorsion of the fallopian tube.^{1,2,4,5}

Herein, we presented three cases of ITT patients referred to tertiary level pediatric surgery center due to paratubal cyst in order to discuss its diagnostic features and surgical management.

2. Case presentations

2.1. Case 1

A 12-year-old sexually inactive postmenarchal female patient was admitted to the emergency department with left lower abdominal pain lasting for 3 days and was referred to pediatric surgery department with an initial diagnosis of acute abdomen. She was admitted to another hospital with a diagnosis of functional ovarian cyst and suggested to be followed-up one year ago. There was no history of trauma and her family history was unremarkable.

The physical examination revealed tenderness and defense in the left lower quadrant. Laboratory tests were within normal limits except elevated white blood cell count (WBC) (12,300/ μ l). The left ovary was invisible and there was a left adnexal complicated mass measuring 70 × 35 × 30 mm in diameter composed of a

* Corresponding author. Department of Pediatric Surgery, Kırıkkale University Faculty of Medicine, Kırıkkale, 71450, Turkey.

E-mail address: drderegunal@yahoo.com (Y.D. Gunal).

Peer review under responsibility of The Emergency Medicine Association of Turkey.

hemorrhagic cyst with internal echoes and simple cystic structures on ultrasound. Doppler ultrasound revealed absence of blood flow on the left adnexa. The patient underwent an emergent exploration.

At laparotomy; uterus, right adnexa and left ovary were normal, but left fallopian tube was twisted twice around itself at clockwise direction. There was a hemorrhagic paratubal cyst 5 × 5 cm in diameter located just near to fimbria. The twisted tube was edematous with purple patchy areas suggesting early signs of ischemia (Fig. 1). The tube was untwisted and the perfusion returned back after waiting several minutes with warm wet gauzes (Fig. 2). The tubal opening was checked with a stilette, and the paratubal cyst was excised totally. The postoperative course was uneventful. Two months later, ultrasound showed normal findings. Histopathological examination revealed simple cyst lined by single layer of tubal type epithelium with hemorrhages. There were no signs of tubal or ovarian pathology during the follow-up with ultrasound for three years.

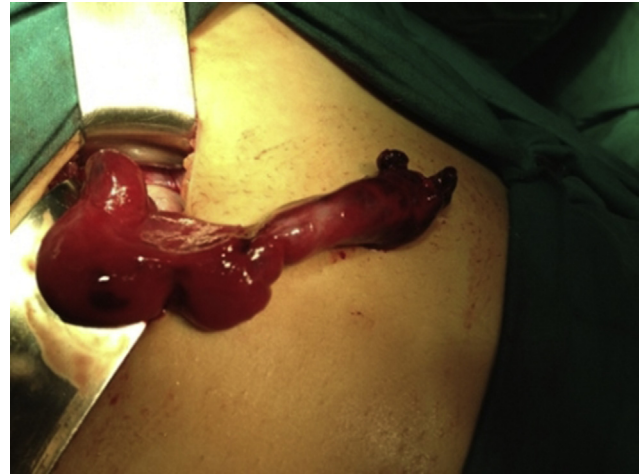

Fig. 2. Fallopian tube after detorsion and cystectomy. (case 1).

2.2. Case 2

A 12-year old premenarche girl was admitted to the emergency department with complaints of abdominal pain, nausea and vomiting for three days and was referred to pediatric surgery department. Her physical evaluation revealed tenderness and defense in the right lower quadrant. She was found to have leukocytosis (20,500/ μ l). The sudden onset of intense pain and microscopic hematuria was detected. There was no significant sign in her ultrasonographic examination. Emergent laparotomy was planned since her complaints continued and her physical examination signs were significant. In her laparotomy, there were diffuse hemorrhagic fluid and proximal right fallopian tube was torsioned four times clockwise. Right fallopian tube was gangrenous. Right ovary, uterus and left adnexa were normal. Ischemic right fallopian tube was detorsioned. After 20 minutes of hot isotonic solution application,

fallopian tube was still gangrenous. Ovary-preserving right salpingectomy was performed. Histopathological evaluation revealed necrotic fallopian tube. There was not any postoperative complication. There were no signs of ovarian pathology during the follow-up with ultrasound for four years.

2.3. Case 3

A 13-year old premenarche girl was admitted to the emergency department with a right lower quadrant pain lasting for 4 hours and was referred to pediatric surgery department. Physical examination revealed left and right lower quadrant pain both and guarding. Laboratory investigations were within normal limits. She had a history of follow-up due to a right ovarian cyst by another institute during last one year. There was a cyst with a diameter of 5.5 cm thought to be arising from right adnexa in pelvic ultrasound and the ovarian blood supply was normal. An emergent laparoscopy was performed due to acute abdomen with a diagnosis of suspected tubal torsion. The right fallopian tube was twisted around itself and the right ovary was normal (Fig. 3). The right fallopian tube was detorsioned and a paratubal cyst was seen and then the cyst was excised totally. The color of the tube was quite normal after detorsion. Although the left ovary was normal there was also a torsioned and pedunculated cyst (Morgagni Hydatide) in the left ovary and it was also excised. Postoperative course was uneventful and histopathologic examination revealed mesonefric paratubal cyst. There were no signs of tubal or ovarian pathology during the follow-up with ultrasound for two years.

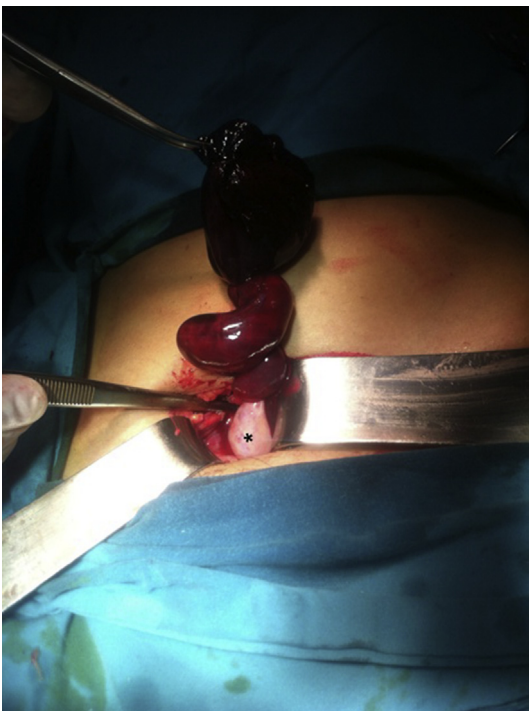


Fig. 1. Twisted fallopian tube with the hemorrhagic sessile paratubal cyst and normal ovary*. (case 1).

3. Discussion

The torsion of fallopian tube without an associating ovarian torsion is called isolated tubal torsion (ITT) and is an uncommon cause of acute abdominal pain in adolescent girls.^{1–3} Although, ITT usually occurs spontaneously, it can also take place due to underlying adnexal pathology such as abnormally long tube/meso-salpinx, premenarchal hormonal activity leading to adnexal congestion and tubal motility, paraovarian/paratubal cysts.^{1–3} Two of three patients in this study were premenarche and the remaining was postmenarche. Although, a paratubal cyst is associated with ITT in two patients, hormonal activity leading to congestion and tubal motility might also be considered as a causative factor.

The diagnosis of ITT is difficult because of nonspecific clinical, laboratory and radiological findings.^{1–3} The presenting symptom is

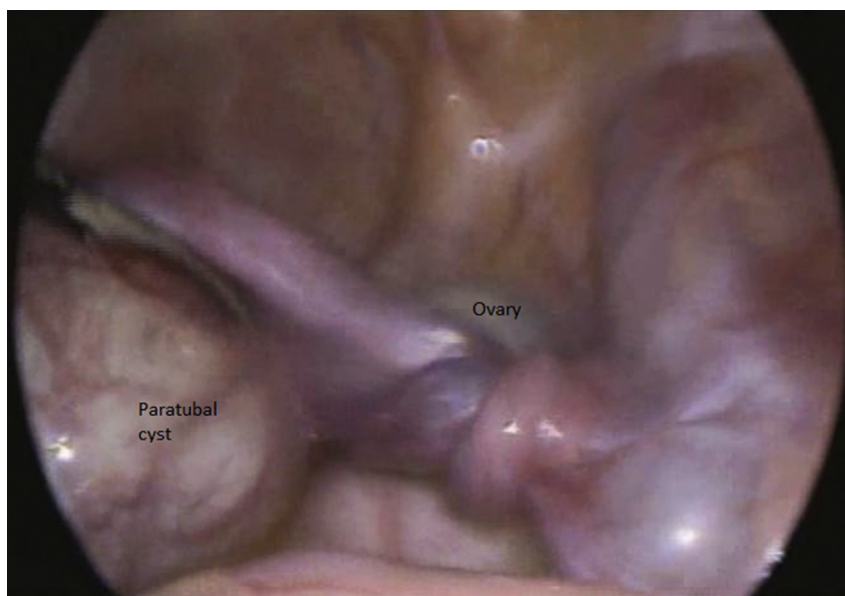


Fig. 3. Twisted fallopian tube with the paratubal cyst and normal ovary. (case 3).

usually sudden onset of intense abdominal pain and physical examination usually reveals abdominal tenderness. Elevated WBC count can be found in laboratory examination and may be a sign of necrosis.^{1,5} There was marked leukocytosis in the second case. Her right fallopian tube was gangrenous and required right salpingectomy. Besides nonspecific clinical findings, there was slightly elevated level of WBC count in the first case. Although the duration of pain was nearly 3 days, she had lower levels of WBC which may be an indicator for the reversibility of the necrosis.

Although there are a few reports describing characteristic findings for ITT, it is not easy to diagnose this rare entity.^{1,3} A cystic mass with internal echoes, tapering near uterus with normal ovary on ultrasound and disturbed blood flow on doppler examination are diagnostic signs.^{3,5–7} However, presence of blood flow does not always rule out the torsion. There may be signs of blood flow in the ovary due to the dual circulation of the ovary, one from the tubes and the other from the uterine artery, especially in isolated tubal torsions. However in our first case we were not able to see the ovary separately on ultrasound and probably that's why we did not see any sign of blood flow in the doppler examination of the left adnexa. CT or magnetic resonance imaging (MRI) can reveal the tubal mass but not signs of ischemia, unlike doppler ultrasound. On the other hand, early diagnosis and management is critically important for preserving the adnexal tissues. ITT was suspected in only one patient (Case 3) preoperatively. We detected a cystic mass on the right adnexa and separately visible right ovary with normal blood flow revealing tubal torsion in this patient. However, the exact diagnose of ITT can be achieved by laparoscopy or laparotomy. Thus, all patients in this study underwent surgical intervention due to acute abdomen. The last patient was treated with laparoscopy without any drawback.

The gold standard of diagnosis and the management of ITT is surgical exploration.^{1–4} The tube should be untwisted, watched for reperfusion and associating pathologies should be investigated during the operation. Unfortunately, salpingectomy is the mostly performed operation in ITT cases due to the difficulty in diagnosis resulting in delayed surgery.^{2,5} The salvage of the tube should be preferred if it is viable because of its importance in future fertility.^{4,5} However, salvage of that tissue has some consequences such as thromboembolism.^{4,8} Furthermore, some authors suggest a

second-look surgery for the cases conservatively managed.² The salvaged tubes should also be followed up for recurrence and viability after the operation.^{2,5} Nevertheless, there are very few studies regarding the long term results of the tube-sparing surgery. It has been reported that the cases with ITT associated with hydrosalpinx and conservatively managed were followed-up for nearly 2 months, and salpingectomy was needed due to recurrence in three of the four cases.² In the present study two patients (Case 1 and 3) had no salpingectomy and were followed-up for three and two years, respectively, and no complication or recurrence were detected. As detorsion and ovarian salvage is a safe treatment option even with a necrotic appearance, the same doctrine may be applied to tubal salvage.

The isolated tubal torsion should be kept in mind in pediatric females presenting to emergency department with lower abdominal pain and acute abdomen findings. Since the clinical and laboratory findings are non-specific, the suspicion is the key point in diagnosis. The surgical management should be performed as soon as possible in order to preserve the fallopian tube because of its importance in future fertility. We suggest laparoscopic approach, as a safe method in the definitive diagnosis and treatment of ITT in such patients, particularly in adolescent girls.

Funding

None declared.

Conflicts of interest

The authors declare that there is no financial relationship and they have no conflict of interest.

References

1. Perlman S, Hertweck P, Fallat ME. Paratubal and tubal abnormalities. *Semin Pediatr Surg.* 2005;14:124–134.
2. Boukaidi SA, Delotte J, Steyaert H, et al. Thirteen cases of isolated tubal torsions associated with hydrosalpinx in children and adolescents, proposal for conservative management: retrospective review and literature survey. *J Pediatr Surg.* 2011;46:1425–1431.
3. Merlini L, Anooshiravani M, Vunda A, et al. Noninflammatory fallopian tube pathology in children. *Pediatr Radiol.* 2008;38:1330–1337.

4. Pampal A, Atac GK, Nazli ZS, et al. A rare cause of acute abdominal pain in adolescence: hydrosalpinx leading to isolated torsion of fallopian tube. *J Pediatr Surg*. 2012;47:131–134.
5. Gaired F, Emil S, Lo A, et al. Laparoscopic treatment of isolated salpingeal torsion in children: case series and a 20-year review of the literature. *J Laparoendosc Adv Surg Tech A*. 2012;22:941–947.
6. Lineberry TD, Rodriquez H. Isolated torsion of the fallopian tube in an adolescent: a case report. *J Pediatr Adolesc Gynecol*. 2000;13:135–138.
7. Vijayaraghavan SB, Senthil S. Isolated torsion of the fallopian tube. *J Ultrasound Med*. 2009;28:657–662.
8. Rizk DEE, Lakshminarasimha B, Joshi S. Torsion of the fallopian tube in an adolescent female: a case report. *J Pediatr Adolesc Gynecol*. 2002;15:159–161.