



Visual diagnosis

Susuk: Mysterious incidental findingPaisal Hussin^a, Maliza Mawardi^{b,*}, Kang Kai Lim^c^a Universiti Putra Malaysia, Department of Orthopaedic, Selangor, Malaysia^b Universiti Putra Malaysia, Department of Family Medicine, Selangor, 43400 Malaysia^c Hospital Serdang, Department of Orthopaedic, Selangor, Malaysia

ARTICLE INFO

Article history:

Received 19 November 2014

Received in revised form

17 December 2014

Accepted 17 December 2014

Available online 10 March 2016

Keywords:

Charm needle

A 66-year-old Malay lady presented to the orthopaedic clinic with complains of body weakness and pain over her left shin. Her problem started 8 years ago after sustaining an open fracture of the

left tibia due to an industrial injury. She was initially managed in a hospital where she undergone wound debridement and external fixation of the fracture. This was followed by open reduction and plating of the left tibia. Her recovery was complicated with osteomyelitis. Throughout the course of treatment, she refused further surgical intervention and eventually defaulted her follow-up. She ended up using complimentary and alternative treatment for her condition. In the orthopaedic clinic, she appeared well and ambulating with the help of a walking frame. On assessment, her vital signs were stable. There were old healed surgical and sinus scars over the lateral and medial aspect of her leg. There was also tenderness over the lateral aspect of her leg with mobile fracture site. Her foot was normal. Neurological assessment performed was normal. Radiographs were performed in view of her pain and previous surgical complication (Fig. 1a–c).

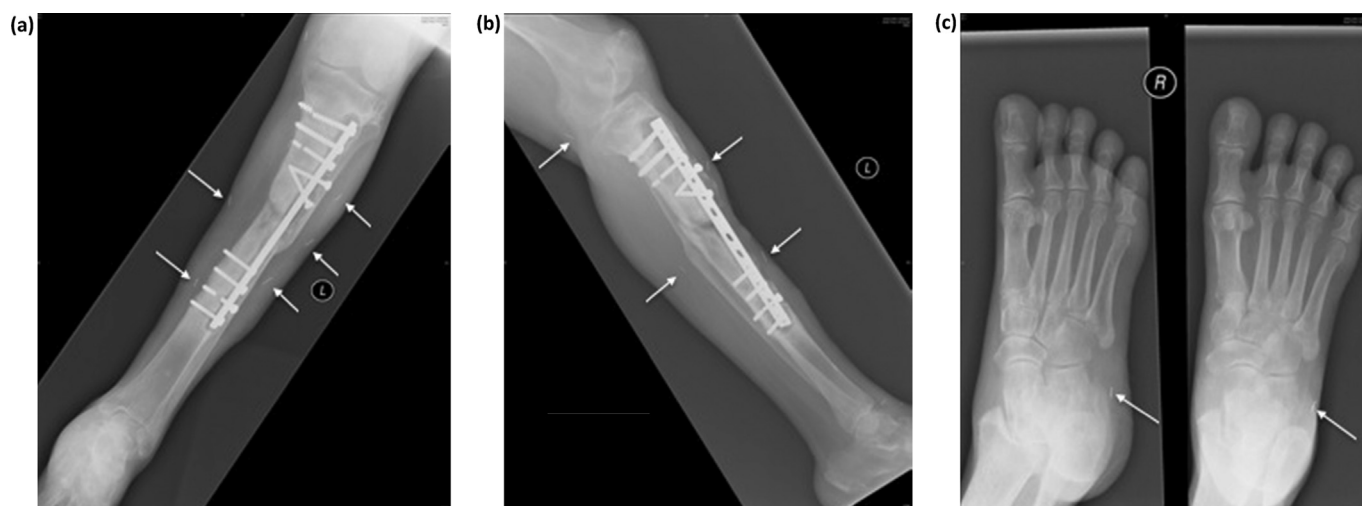


Fig. 1. (a) Antero-posterior radiograph of the left leg. (b) Lateral radiograph of the left leg. (c) Oblique and antero-posterior radiograph of the right foot.

* Corresponding author. Tel.: +60 389472538.

E-mail address: maliza_mawardi@upm.edu.my (M. Mawardi).

Peer review under responsibility of The Emergency Medicine Association of Turkey.

Diagnosis: susuk (charm needles)

The use of charm needles, or *susuk*, is a common traditional practice among the Southeast Asia region including Malaysia, Singapore, and Indonesia.^{1–3} These are metallic objects resemble needles with diameters ranging from 0.5 to 1.0 mm in diameter and 5–10 mm in length. They are inserted subcutaneously by traditional healers in various parts of the body, including the face, limbs, torso, joints, and the genitals. The objective of insertion is mainly for general well being, cure for diseases, invincibility or even for sexual prowess, which depends on the locality of insertion.^{2,4,5} The practice of the charm needle insertion is a cultural practice rather than religious belief.

Susuk are made from metal such as gold, copper, or silver.⁵ These materials are easily detected upon radiograph examination. The inserted *susuk* may remain intact for years but may also could be fragmented by corrosion. To date, no reports have stated any complications from the use of *susuk*, even if it had a tendency to migrate elsewhere.

Susuk is taboo among certain communities. Most patients do not give their treatment history voluntarily because they want to ensure the potency and efficacy. They are warned before hand

about 'bad karma' that may ensue if the compliance with the prohibition of the wearer is not met.² *Susuk* is inserted into the skin of the wearer during a special ritual by a painless gentle rub with no external signs or swelling. *Susuk* can easily be mistaken as parts of a broken acupuncture needle or introduced from trauma. Therefore, pain may be misdiagnosed by an unaware physician and this benign condition may eventually be mismanaged.

There is an increase of migration across the globe, especially those from Southeast Asia region, and awareness about this unique practice will help in avoidance of misdiagnosis and mismanagement of the patient. *Susuk* should only be removed if it is found to be the causative problem, such as infection.

References

1. Alhamad T. *Susuk*. *Am J Respir Crit Care Med*. 2011;183:484.
2. Nor M, Yushar A, Razali M, Ramli R. Incidental radiological finding of *susuk* in the orofacial region. *Dentomaxillofac Radiol*. 2006;35:473–474.
3. Teo SK. A woman with hidden charm needles. *J R Coll Physicians Edinb*. 2006;36:211–212.
4. Pande S. Incidental findings of *susuk* in orthopaedic patients. *Brunei Int Med J*. 2011;7:177–180.
5. Pothiwala S. Incidental radiological finding of charm needles. *Hong Kong J Emerg Med*. 2012;19:141–143.