



## Case report

## Biventricular thrombus in hypereosinophilic syndrome presenting with shortness of breath

Abdul Baqi<sup>a</sup>, Shahan Waheed<sup>b,\*</sup>, Fateh Ali Tipoo<sup>a</sup>, Aamir Hameed Khan<sup>a</sup><sup>a</sup> Department of Cardiology, Aga Khan University Hospital, Pakistan<sup>b</sup> Department of Emergency Medicine, Aga Khan University Hospital, Karachi, Pakistan

## ARTICLE INFO

## Article history:

Received 23 March 2015

Received in revised form

20 April 2015

Accepted 11 May 2015

Available online 8 May 2016

## Keywords:

Hypereosinophilic syndrome  
Thrombus

## ABSTRACT

A 48 years old male presented to clinic with 12 months of low grade fever with shortness of breath which has progressively worsened with no associated weight loss, night sweats or loss of appetite. There was no prior history of chronic illness before the current illness. Laboratory workup revealed a high white blood cell count with predominant eosinophils. Chest X-ray was normal. Transthoracic echocardiography and Cardiac Magnetic Resonance showed biventricular thrombi. On further extensive workup the findings were consistent with hypereosinophilic syndrome. The patient was started on oral steroids, hydroxyurea, imatinib mesylate and oral anticoagulation. The patient responded to the treatment with complete resolution of his symptoms over the course of few months. The repeat Echocardiogram after a year showed normal left ventricular systolic and diastolic function with complete resolution of biventricular thrombi.

Copyright © 2016 The Emergency Medicine Association of Turkey. Production and hosting by Elsevier B.V. on behalf of the Owner. This is an open access article under the CC BY-NC-ND license (<http://creativecommons.org/licenses/by-nc-nd/4.0/>).

## 1. Background

Idiopathic hypereosinophilic syndrome (HES) is a rare heterogeneous leukoproliferative disorder with unexplained hypereosinophilia and multi-organ system dysfunction.<sup>1</sup> The main diagnostic criteria for HES include (1) hypereosinophilia-persistence of 1500 eosinophils/uL lasting > 6months, (2) no evidence of allergic, parasitic, or other cause associated with hypereosinophilia, and (3) evidence of organ damage (nervous system, lungs, heart, or bone marrow).<sup>2</sup> We are presenting a first ever reported case of idiopathic hypereosinophilic syndrome from Pakistan with biventricular apical thrombus confirmed with echocardiography and cardiac magnetic resonance. Our case is unique because of the unusual presentation of the thrombus with idiopathic hypereosinophilic syndrome. Also this is the first case which is reported from Pakistan, we have excluded all the major differentials of hypereosinophilia. Our patient responded to oral steroids, imatinib mesylate and hydroxyurea for eosinophilia and ACE inhibitor for

left ventricular diastolic dysfunction. The patient was followed regularly for 1 year with full recovery of symptoms, normalization of left ventricular diastolic dysfunction and persistence of biventricular thrombi.

## 2. Case presentation

A 48 years-old male with no prior chronic illnesses presented to out-patient department of our hospital with complaint of low grade fever and shortness of breath for 12 months with no associated night sweats, weight loss or loss of appetite. There was no history of travel or contact with the sick. On examination the patient was hemodynamically stable. Chest was clear with normal vesicular breathing, cardiovascular examination was unremarkable, abdomen was soft with no visceromegaly, Central nervous system examination was normal and there was no lymph node palpable. Because of his chronic illness which was progressing he was admitted to hospital for workup.

## 3. Investigations

Initial work up revealed high WBC ( $22 \times 10^9/L$ ) count with predominant Eosinophils of 43%. Hemoglobin and platelets were within normal limits. ESR was 53 mm/h. Chest x-ray was negative for pulmonary edema, infiltrates or fibrotic changes. We considered

\* Corresponding author. Stadium Road Karachi, 74700 Karachi, Pakistan. Tel.: +92 33331734.

E-mail address: [docshahan83@hotmail.com](mailto:docshahan83@hotmail.com) (S. Waheed).

Peer review under responsibility of The Emergency Medicine Association of Turkey.

bronchial asthma, eosinophilic pneumonia, parasitic infection, churg-strauss syndrome, malignancies and Hypereosinophilic syndrome as differential diagnoses to explain this eosinophilia. There were no parasitic eggs or larvae in his stool and results of sera anti-Aspergillus antibody tests were negative (to exclude parasitic infection). Spirometry was negative for any obstructive or restrictive lung pathology. Computed tomography (CT) scan detected no abnormalities in the lungs (eosinophilic pneumonia was excluded) liver, gall bladder, pancreas and kidneys. Among six diagnostic criteria for churg-strauss syndrome (CSS), only eosinophilia was fulfilled. In addition, tests for anti-neutrophil cytoplasmic antibodies (ANCA) were negative. Therefore, CSS was unlikely. Tumor markers were measured, carcinoembryonic antigen (CEA), Squamous cell carcinoma (SCC), a-fetoprotein (AFP) were all negative. Echocardiography (ECHO) was done to rule out any possible causes of shortness of breath in this patient, ECHO revealed normal left ventricular systolic function but with Grade II left ventricular diastolic dysfunction and no valvular pathology (Fig. 1). ECHO also revealed echogenic densities in right and left ventricular apices, those were consistent with apical thrombi. Due to these findings cardiac Magnetic resonance imaging (CMRI) was done to confirm the echo findings, CMRI showed normal left ventricular volumes with normal left ventricular systolic function, a thin rim of left ventricular apical thrombus and findings on late gadolinium images were consistent with the diagnosis of endomyocardial fibrosis secondary to HES (Fig. 2). Further evaluation of eosinophilia including,

FIP1-like 1/platelet-derived growth factor receptor  $\alpha$  (FIP1L1-PDGFR $\alpha$ ) fusion gene test was positive. Bone marrow biopsy was done which was positive for marked eosinophilia with hypercellular bone marrow exhibiting markedly increased Eosinophils. Based on these results, HES was diagnosed.

#### 4. Treatment

Patients with symptomatic hypereosinophilia should be managed emergently with high doses of glucocorticoids; an initial dose of 1 mg/kg/day for a total duration of 1–2 weeks, then tapered down to the lowest effective dose that maintains remission.<sup>3–5</sup> Patients with positive FIP1L1/PDGFR $\alpha$  fusion gene should be treated more aggressively with imatinib mesylate.<sup>4,6,7</sup> The patient was started on oral steroid and hydroxyurea and imatinib mesylate for eosinophilia, along with ACE inhibitor for left ventricular diastolic dysfunction and oral anticoagulation for apical thrombi, and PT/INR was kept in the range of 2–3.

#### 5. Outcome and follow up

The Patient was followed regularly in out-patient department for symptoms, eosinophil counts and echocardiography for one

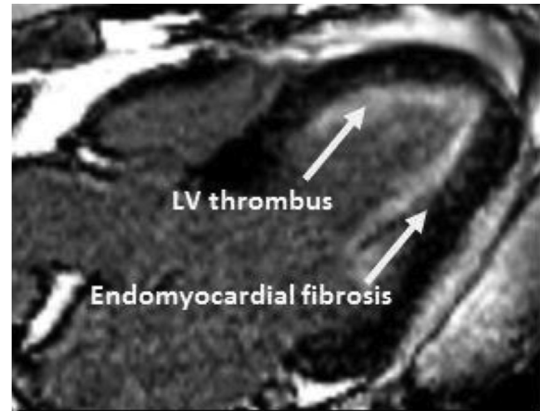


Fig. 2. CMR, showing endomyocardial fibrosis and LV apical thrombus.

year. He has no fever and shortness of breath now and repeat ECHO showed normal left ventricular systolic as well as diastolic function, with complete resolution of thrombi from both apices and last WBC count is ( $8 \times 10^9/L$ ) with Eosinophil of 0.9%. Hemoglobin and platelets are within normal limits.

#### 6. Discussion

HES is a disorder seen in young to middle-age patients. It is more common in men compared to women.<sup>3,8–10</sup> The disease is characterized by unexplained hypereosinophilia that can involve different organ systems. Cardiac involvement is found in about 60% of patients and is the predominant cause of morbidity and mortality in this syndrome.<sup>11</sup> This case is significant because it fulfills all of the main criteria of HES, with bilateral ventricular apical thrombus and fibrotic changes. In the present case report we will be discussing on three points.

First, the echocardiography findings are the obliteration of the apex of the left or right ventricle, or both by the laminar thrombus, and the endomyocardial fibrosis in the late fibrotic stage of the cardiac involvement. HES most commonly involves the posterior wall of the left ventricle, posterior mitral valve leaflet resulting in mitral regurgitation and involvement of the papillary muscles.<sup>12</sup> The echocardiographic findings in our case revealed normal left ventricular systolic function but with grade II left ventricular diastolic dysfunction and no valvular pathologies. It also revealed echogenic densities in right and left ventricular apices that were consistent with apical thrombi. The posterior mitral leaflet was not involved and also there was no involvement of the papillary muscles.

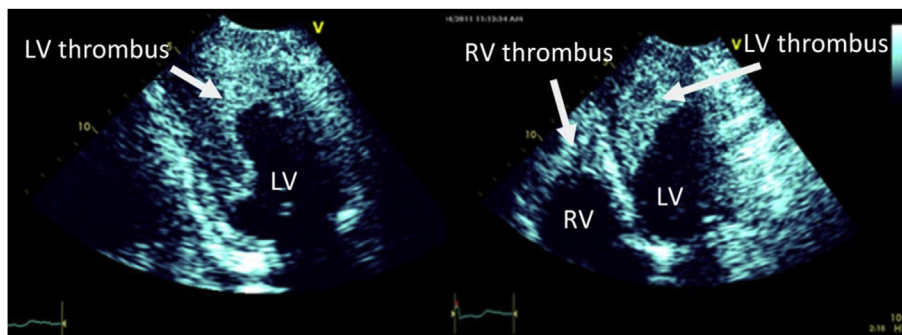


Fig. 1. Transthoracic ECHO, showing large thrombi in ventricles.

Second, the cardiac magnetic resonance imaging (CMRI) was done to confirm our echo findings which were consistent with the echocardiography findings of normal ventricular volumes and normal left ventricular systolic function. On late gadolinium images a thin rim of left ventricular apical thrombus was appreciated in concordance with the diagnosis of endomyocardial fibrosis. The findings of our CMRI did not show the diffuse circumferential subendocardial high signal intensity in the midcavity and apical segments after gadolinium contrast administration. Also there was no acute myocardial edema with the same distribution of the intracavitary thrombus at the right ventricle and left ventricle apex which are consistent with high C-reactive protein levels in our patient. The left ventricular cavity was also not dilated in our patient.

Third, our patient was tested for the gene abnormality which was positive. We started oral steroids, imatinib mesylate which is the recommended therapy in FIPILI-PFGFRA positive patients.<sup>4,6,7</sup> We started our patient oral anticoagulation with the aim of INR in the range of 2–3. The ACE inhibitor was started for his left ventricular dysfunction. On follow up our patient responded to the above measures and the repeat echocardiogram demonstrated normal left ventricular systolic and diastolic function with complete resolution of the thrombus.

### Contributions

All authors have seen and approved the manuscript, contributed significantly to the work, and also that the manuscript has not been previously published nor is not being considered for publication elsewhere.

### Competing interests

None.

### Author details

Dr. Abdul Baqi, Dr. Shahan Waheed, Dr. Fateh Ali Tipoo Sultan and Dr. Amir Hameed Khan from Department of medicine, section of Cardiology, Aga Khan University Hospital Karachi.

### Acknowledgments

We are happy to present this case report to those who may wish to validate our results. All the laboratory data, from which the identification information was deleted, are available from the corresponding author upon request.

### References

1. Eisa N, Shaheen K, Alraiyes AH, et al. *BMJ Case Rep.* 2013. <http://dx.doi.org/10.1136/bcr-2013-009609>.
2. Chusid MJ, Dale CD, West BC, Wolff SM. The hypereosinophilic syndrome: analysis of fourteen cases with review of the literature. *Med Baltim.* 1975;54:1–27.
3. Weller PF, Bubley GJ. The idiopathic hypereosinophilic syndrome. *Blood.* 1994;83:2759–2779.
4. Sheikh J, Weller PF. Clinical overview of hypereosinophilic syndromes. *Immunol Allergy Clin North Am.* 2007;27:333–355.
5. Rapanotti MC, Caruso R, Ammatuna E, et al. Molecular characterization of paediatric idiopathic hypereosinophilia. *Br J Haematol.* 2010;151:440–446.
6. Podjasek JC, Butterfield JH. Mortality in hypereosinophilic syndrome: 19 years of experience at Mayo Clinic with a review of the literature. *Leuk Res.* 2013;37:392–395.
7. Fauci AS, Harley JB, Roberts WC, et al. NIH conference. The idiopathic hypereosinophilic syndrome. Clinical, pathophysiologic, and therapeutic considerations. *Ann Intern Med.* 1982;97:78–92.
8. Winn RE, Kollef MH, Mayer JI. Pulmonary involvement in the hypereosinophilic syndrome. *Chest.* 1994;105:656–660.
9. Spry CJ. The hypereosinophilic syndrome: clinical features, laboratory findings and treatment. *Allergy.* 1982;37:539–551.
10. Sykes JE, Weis DJ, Buoen LC, Blauvelt MM, Hayden DW. Idiopathic hypereosinophilic syndrome in 3 rottweilers. *J Vet Intern Med.* 2001;15:162–166.
11. Corssmit EP, Trip MD, Durrer JD. Löffler's endomyocarditis in the idiopathic hypereosinophilic syndrome. *Cardiology.* 1999;91:272e276.
12. Feigenbaum H, Armstrong WF, Ryan T. *Feigenbaum's Echocardiography.* 6th ed. Philadelphia: Lippincott Williams & Wilkins; 2005:752.