

Weakness in the Emergency Department: Hypokalemic Periodic Paralysis Induced By Strenuous Physical Activity

Nurettin Ozgur DOGAN, Nazire AVCU, Elif YAKA, Ali ISIKKENT, Ugur DURMUS

Department of Emergency Medicine, Kocaeli University Faculty of Medicine, Kocaeli, Turkey

SUMMARY

Hypokalemic periodic paralysis is a rare but serious disorder that is typically caused by a channelopathy. Thyrotoxicosis, heavy exercise, high carbohydrate meal and some drugs can trigger channelopathy in genetically predisposed individuals. A 33-year-old male patient presented to the emergency department with weakness in the lower extremities. He stated that he had done heavy physical activity during the previous week. The patient exhibited motor weakness in the lower extremities (2/5 strength) during the physical examination. Initial laboratory tests showed a potassium level of 1.89 mEq/L. The initial electrocardiogram demonstrated T wave inversion and prominent U waves. The patient was treated in the emergency department with oral and intravenous potassium. The physical and ECG symptoms resolved within 16 hours of potassium supplementation and biochemical tests showed normal serum potassium levels. The patient was discharged shortly after the resolution of the symptoms. Weakness is an important but nonspecific symptom that may be brought on by a number of underlying physiological processes. Hypokalemic periodic paralysis is a rare disease that may be triggered by heavy physical activity and presents with recurrent admissions due to weakness.

Key words: Emergency department; hypokalemic periodic paralysis; muscle weakness.

Introduction

Hypokalemic periodic paralysis (HPP) is a rare and episodic disorder presenting with muscle weakness and fatal dysrhythmias secondary to deep hypokalemia.^[1-3] HPP occurs as a result of both primary (hereditary) and secondary causes, some of the which are preventable. Primary causes are familial with autosomal dominant inheritance of point mutations in the calcium channel subunit CACNA1S, whereas secondary causes include thyrotoxicosis, hyperaldosteronism, renal tubular acidosis, barium intoxication, and either legal or illicit drug use (laxatives, diuretics, corticosteroids, thyroid hormone pills).^[2,4,5]

Regardless of the underlying etiology, acute attacks may be triggered by heavy exercise, viral infection, insomnia, high carbohydrate diet, cold and other stress factors.^[2] Although the primary goal of treatment is to restore serum potassium to normal physiologic levels, fatal dysrhythmia secondary to rebound hyperkalemia has been reported in patients with HPP as a result of the delayed release of potassium stores.^[6]

Here we report a case of hypokalemic periodic paralysis presenting with symptoms of hypokalemia and electrocardiographic manifestations.

Submitted: May 25, 2014 **Accepted:** June 23, 2014 **Published online:** March 04, 2015

Correspondence: Nurettin Ozgur DOGAN, M.D. Kocaeli Universitesi Tip Fakultesi, Acil Tip Anabilim Dalı, Umutepe Kampusu, Kocaeli, 41000 Izmit, Turkey.

e-mail: nurettinozgurdogan@gmail.com



Case Report

A 33-year-old male patient presented to the emergency department with weakness and spasms in the lower extremities. His primary complaint was weakness and the inability to walk in the morning hours. The patient was free of systemic illnesses and denied the use of medications or illicit/herbal drugs. The patient's diet had not changed recently. The patient reported having a similar episode five years ago during which time he was admitted to the neurology department. He was discharged from the hospital after potassium supplementation restored the patient's muscular strength. During this prior episode biochemical tests showed that thyroid function, vitamin B12, and folic acid levels were in the normal range. The patient stated that he had been conducting heavy physical activity during the previous week.

In the emergency department, the patient was conscious and oriented. His vital signs included a temperature of 35 °C, blood pressure of 140/77 mm Hg, respiratory rate of 24 breaths/minute, and pulse rate of 73 beats/minute. In the physical examination, the patient had motor weakness in both the lower extremities (2/5 strength) and upper extremities (4/5 strength). Deep tendon reflexes were diminished. Sensorial examination and cerebellar tests were normal. Initial laboratory tests showed deep hypokalemia

(K: 1.89 mEq/L; normal range 3.5-5.5 mEq/l) and hyperchloremia (Cl: 117 mEq/L; normal range 98-107 mEq/L). Other electrolytes, renal, liver function tests, complete blood count, and coagulation parameters were within normal ranges. In 12-lead electrocardiogram, a sinus rhythm with marked T wave inversion and prominent U waves was demonstrated (Figure 1).

The patient was treated in the emergency department with oral and intravenous potassium (4.68 g oral and 120 mEq/L intravenous potassium) with the goal of achieving a serum potassium level greater than 3.0 mEq/L. Intravenous potassium replacement was achieved with intermittent infusion of potassium to avoid cardiac side effects. Sixteen hours after the start of the treatment the physical examination findings improved and the patient started to walk again. The patient was referred to endocrinology and continuation of the treatment was advised. At discharge, serum potassium levels had increased to 4.91 mEq/L and motor strength in the extremities was 5/5. The electrocardiogram was normal and hypokalemia symptoms had completely resolved (Figure 2). Regarding the patient's previous admissions to the ED for similar episodes of weakness, a diagnosis of hypokalemic periodic paralysis was established and an outpatient follow-up was advised.

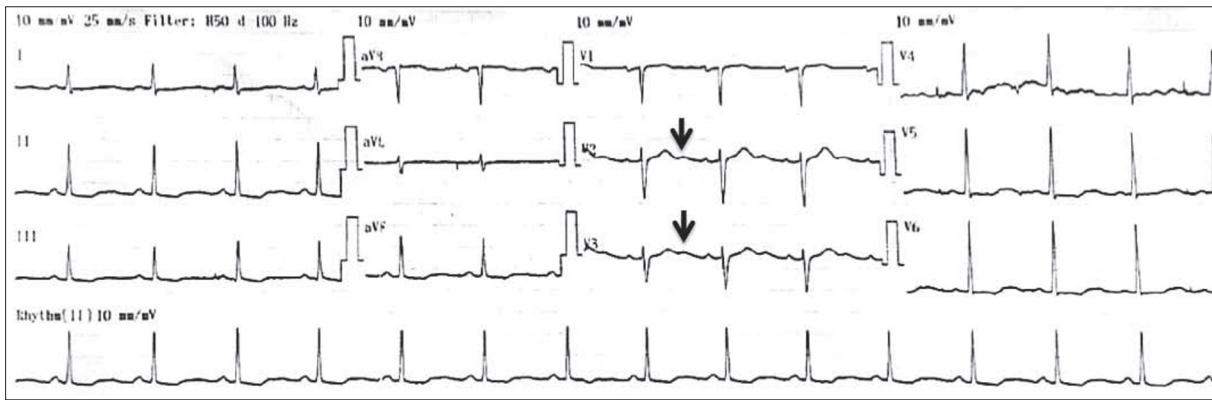


Figure 1. ECG at the presentation to the ED (U-waves were shown with black arrows).

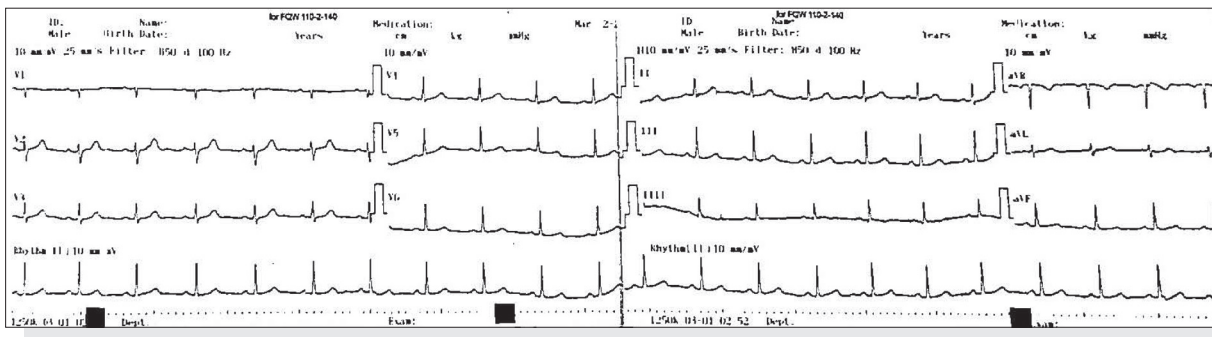


Figure 2. ECG at discharge from ED.

Discussion

Hypokalemic periodic paralyzes are a heterogenous group of diseases that are more prevalent in young men of Asian origin. Although channelopathies resulting from genetic predisposition play an important role in development of the disease, a considerable number of cases are diagnosed as idiopathic.^[5] The present case was previously evaluated for secondary causes of hypokalemia, however the diagnosis of HPP was not established at that time. Therefore the patient did not recognize the signs and symptoms of the disease and the association with potentially precipitating factors.

Patients with hypokalemic periodic paralysis usually present with symmetric motor weakness, which was noted by the present case in the early morning hours.^[1,4,7] A differential diagnosis with a broad spectrum of diseases including Guillain-Barre syndrome, myasthenia gravis, spinal cord diseases, and proximal myopathies, is necessary to rule out other causes of the periodic paralysis. In addition, endocrinologic and nephrologic disorders including thyrotoxicosis, Gitelman syndrome, renal tubular acidosis, and hyperaldosteronism should be considered.^[5] These disorders may be distinguished based upon clinical presentation, acid-base status, and accompanying electrolyte disorders. In the absence of objective motor deficits, electrocardiographic manifestations including ST-segment depression, T-wave inversion, and prominent U waves may indicate severe underlying hypokalemia. The present case presented with prominent U waves in the precordial leads and ST-segment depression in the initial ECG. At the initial presentation, the patient had paraparesis and the medical team initially considered disorders involving the spinal cord such as spinal tumor, transverse myelitis, or pathologic fractures of the vertebrae. However the repetitive nature of the symptoms, the ECG features, and low potassium levels suggested a metabolic disorder rather than a neurologic problem. In conjunction with ECG findings, the episodic character of his paraparesis suggested a possible diagnosis of hypokalemic paralysis.

Thyrotoxicosis has been proposed as one of the important secondary causes of HPP as a result of increased potassium influx into the cells via the sodium/potassium ATPase pump.^[4,6-9] Total body potassium stores may be inherently sufficient and vigorous potassium replacement can cause significant harm, including hyperkalemia-associated dysrhythmias.^[6] Thyroid hormone levels may contribute to diagnosis in cases of thyrotoxic HPP, however this patient was previously evaluated for hyperthyroidism during the prior hypokalemic episode. Nevertheless, the medical team cautiously replaced potassium using both oral and intravenous routes.

Strenuous physical activity is widely accepted as an important trigger of HPP. A case series conducted by Wong reported that three of ten patients with thyrotoxic HPP experienced physical exhaustion prior to the onset of symptoms.^[7] Patients with HPP may report a high carbohydrate meal, lack of sleep, and physical or psychological stress as precipitating factors. Although the present patient was previously evaluated for secondary causes for hypokalemia, heavy exercise is likely to have precipitated the attack.

Hypokalemic periodic paralysis predominantly affects patients of Asian descent; etiological causes remain heterogeneous and unclear. Before a diagnosis with HPP can be established, secondary causes, including various endocrinologic disorders, should be evaluated. If HPP is suspected, careful repletion of potassium with cardiac monitoring reduces the incidence of fatal arrhythmogenic complications. Emergency physicians should be aware of the signs and symptoms of HPP and its manifestations.

Conflict of Interest

The authors declare that there is no potential conflicts of interest.

References

1. Alkaabi JM, Mushtaq A, Al-Maskari FN, Moussa NA, Gariballa S. Hypokalemic periodic paralysis: a case series, review of the literature and update of management. *Eur J Emerg Med* 2010;17:45–7. [CrossRef](#)
2. Incecik F, Hergüner MO, Altunbaşak S, Lehman-Horn F. Hypokalemic periodic paralysis due to the SCN4A R672H mutation in a Turkish family. *Turk J Pediatr* 2010;52:409–10.
3. Fraer M. A mask and many faces: hypokalemic periodic paralysis. *South Med J* 2008;101:887. [CrossRef](#)
4. Doğan NÖ, Dođru C, Demircan A, et al. Thyrotoxic hypokalemic periodic paralysis presenting with paraparesis. *Nobel Med* 2013;9:118–20.
5. Maurya PK, Kalita J, Misra UK. Spectrum of hypokalaemic periodic paralysis in a tertiary care centre in India. *Postgrad Med J* 2010;86:692–5. [CrossRef](#)
6. Ahmed I, Chilimuri SS. Fatal dysrhythmia following potassium replacement for hypokalemic periodic paralysis. *West J Emerg Med* 2010;11:57–9.
7. Wong P. Hypokalemic thyrotoxic periodic paralysis: a case series. *CJEM* 2003;5:353–5.
8. Antonello IC, Antonello VS, de Los Santos CA, de Almeida N, d'Avila DO. Thyrotoxic hypokalemic periodic paralysis: a life-threatening syndrome. *Eur J Emerg Med* 2009;16:43–4. [CrossRef](#)
9. Gorchynski J, Nwosu H, Frame J. Acute ascending paralysis presenting as an endocrine emergency. *Am J Emerg Med* 2009;27:371.e1–371.e3. [CrossRef](#)